

FORPATH

Histoséminaire de lames

Anne-Catherine Baglin
Suresnes - France

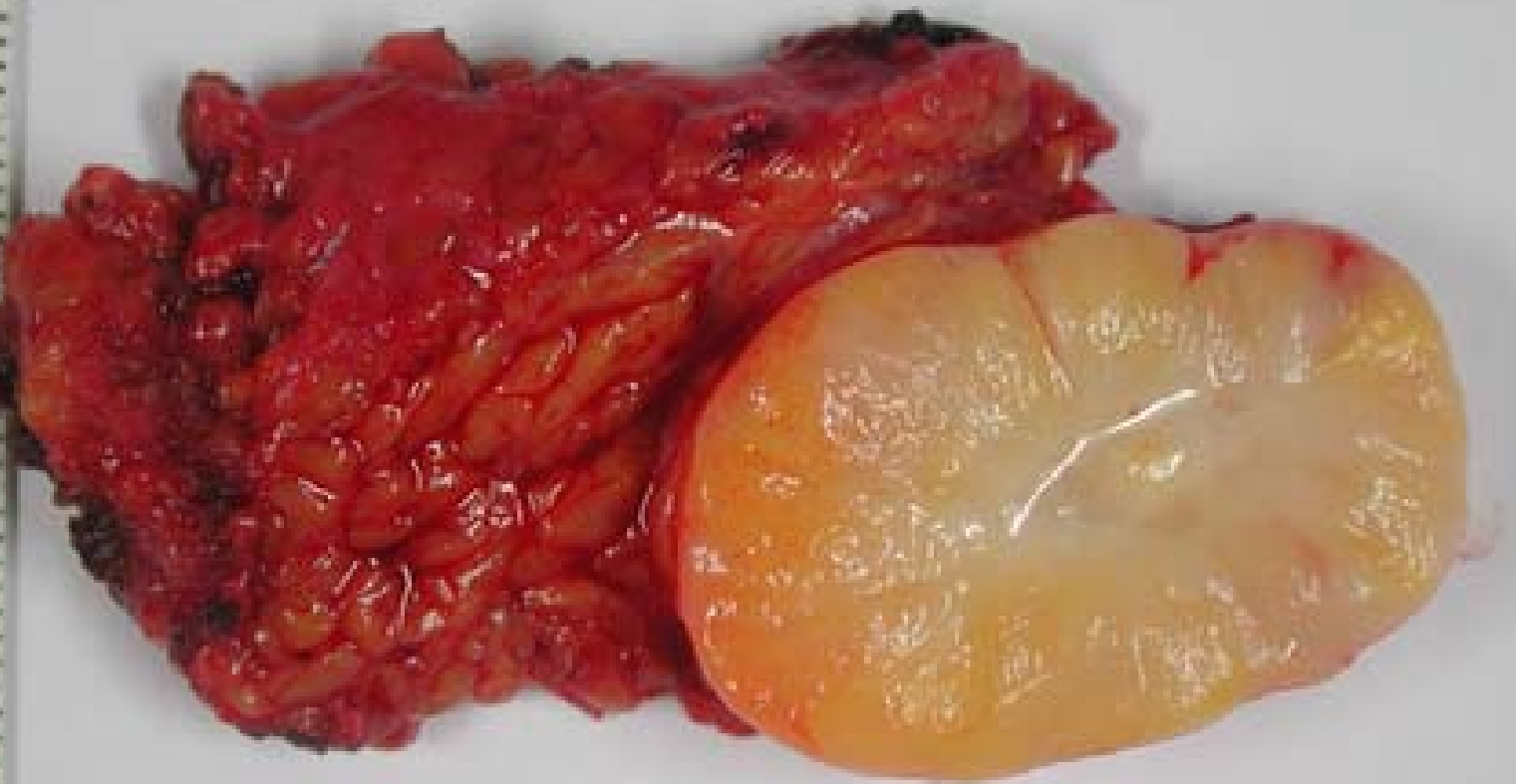Bruxelles 24 avril 2010



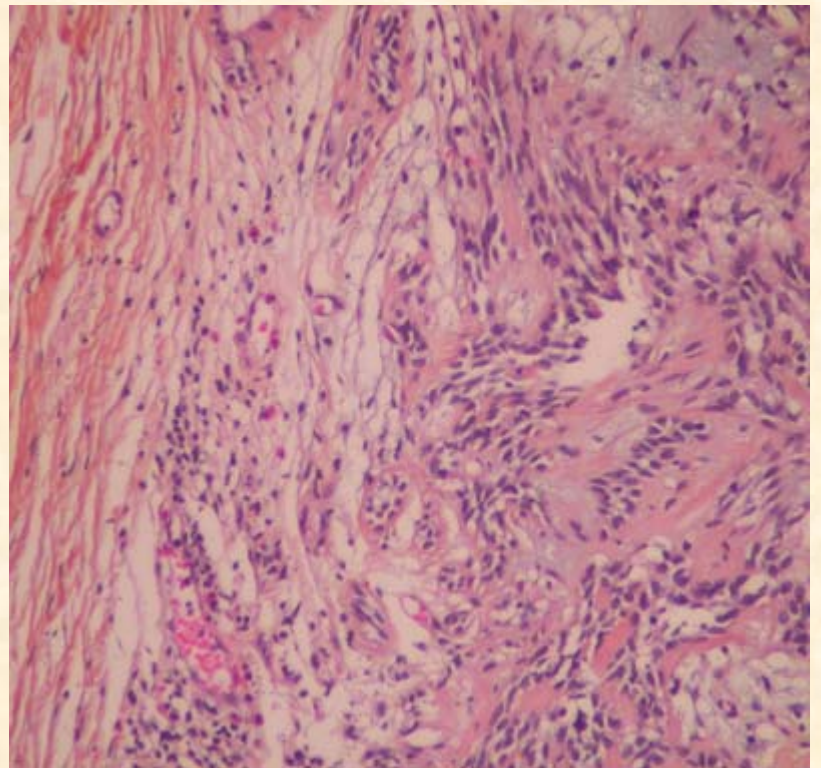
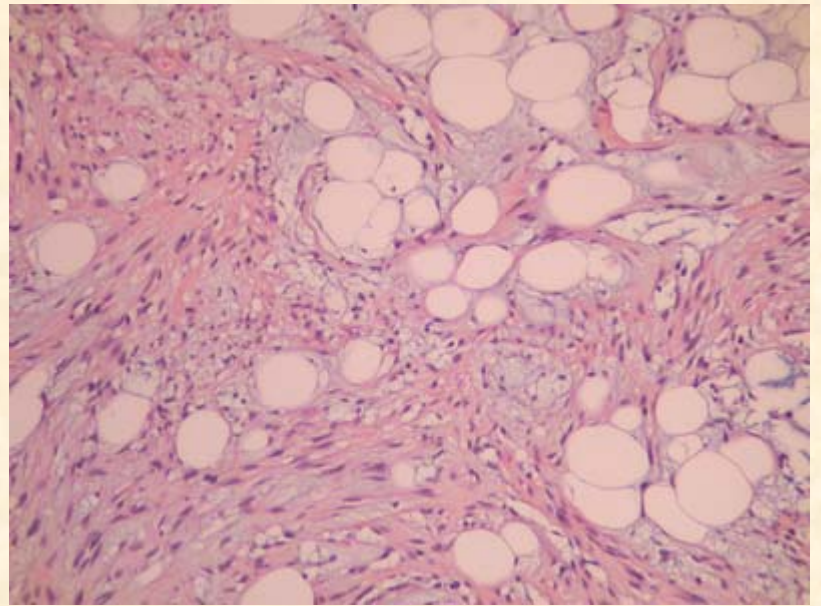
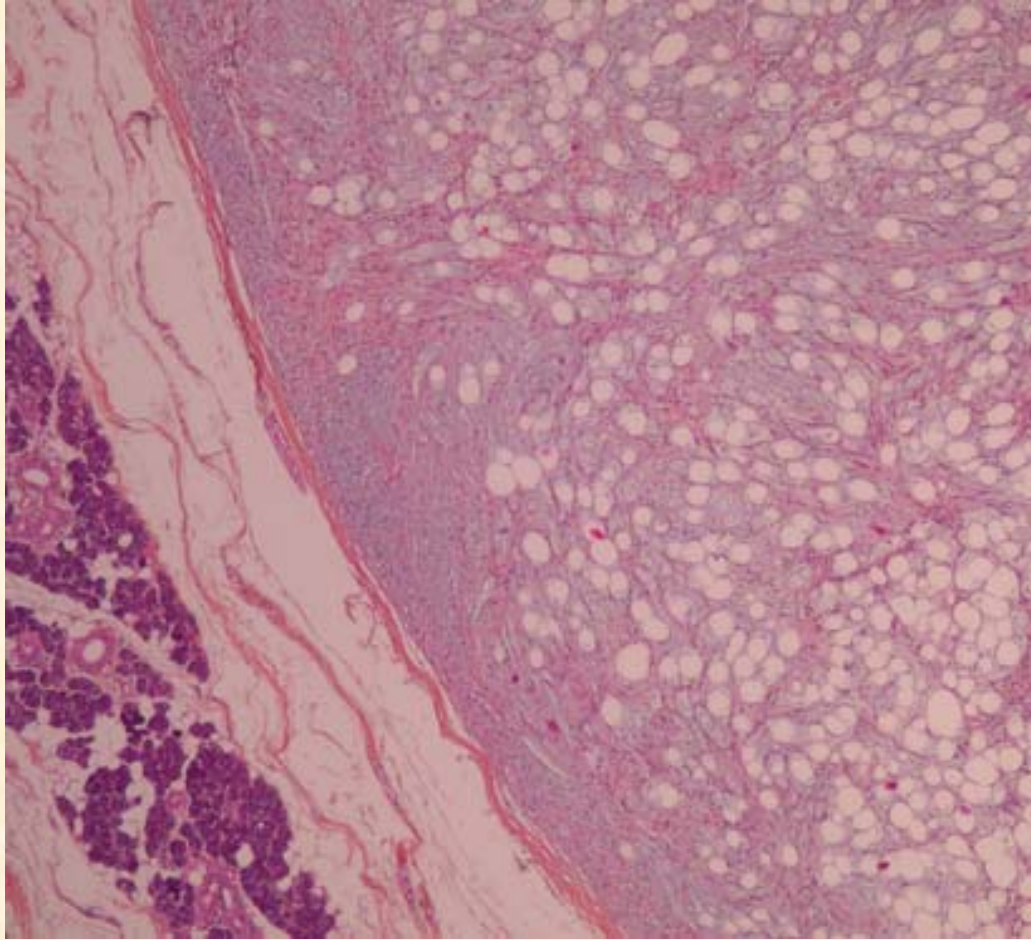
Cas n°1

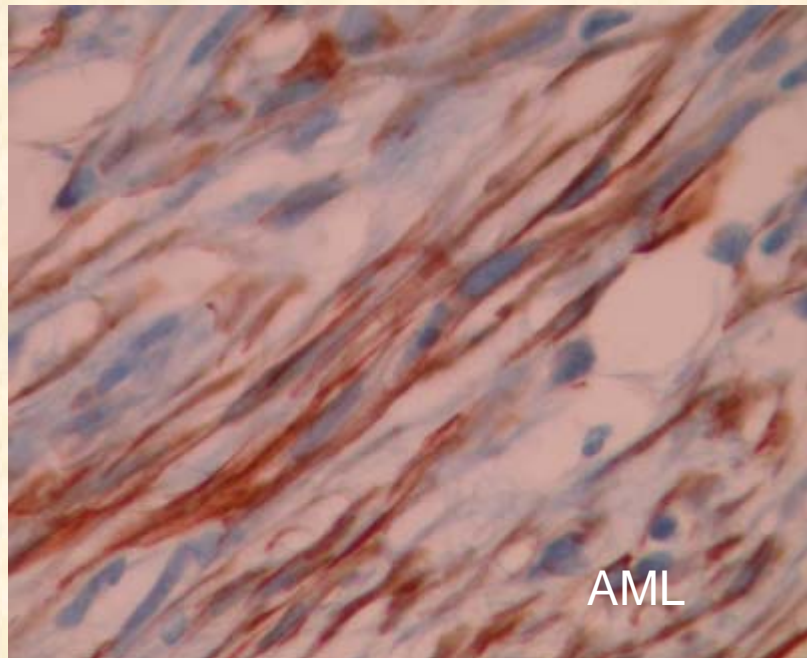
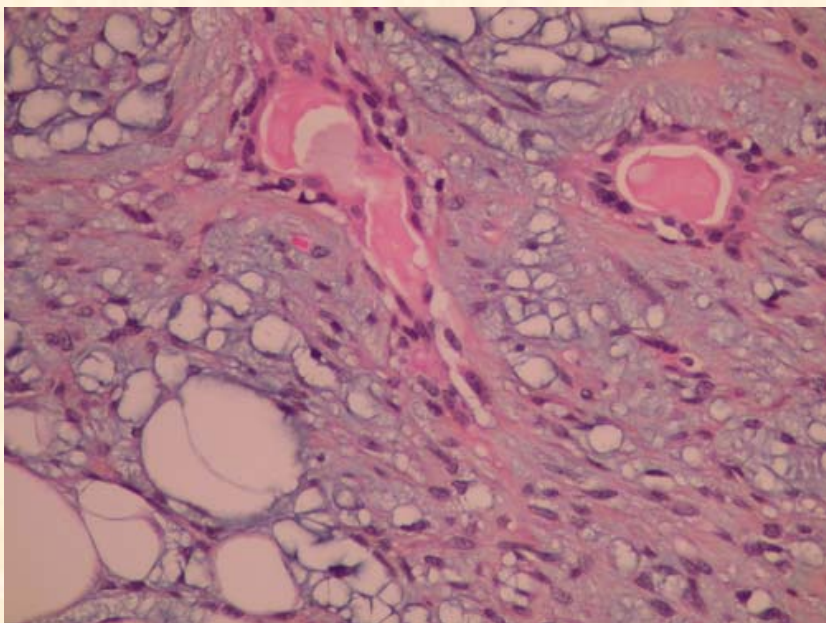
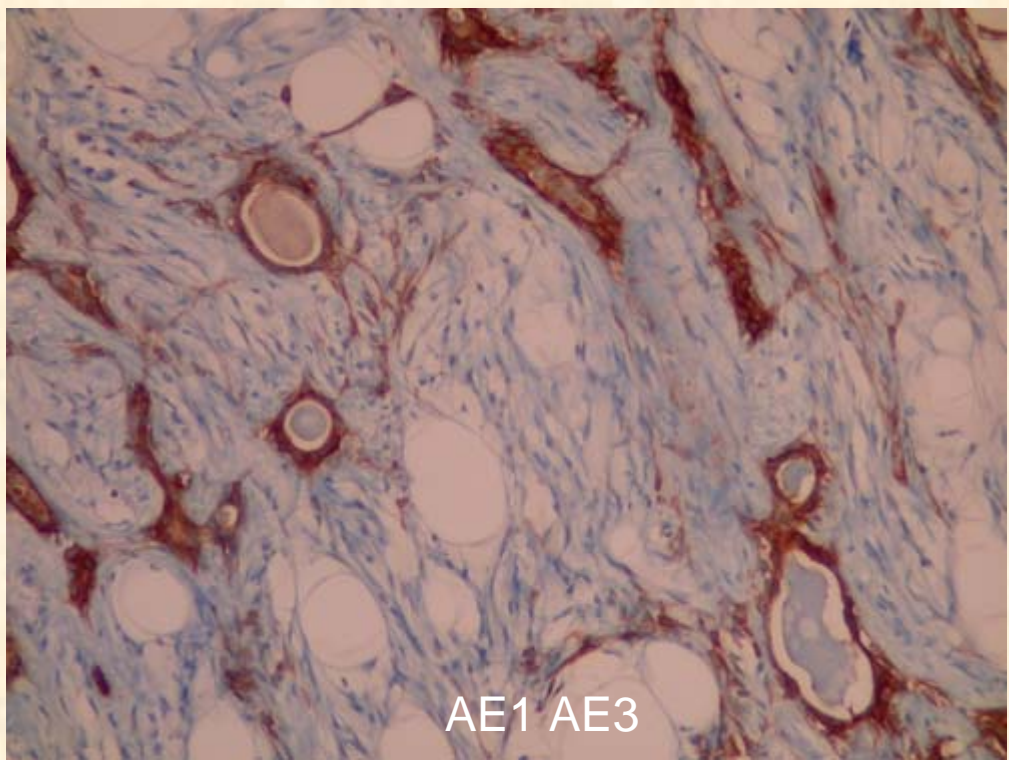
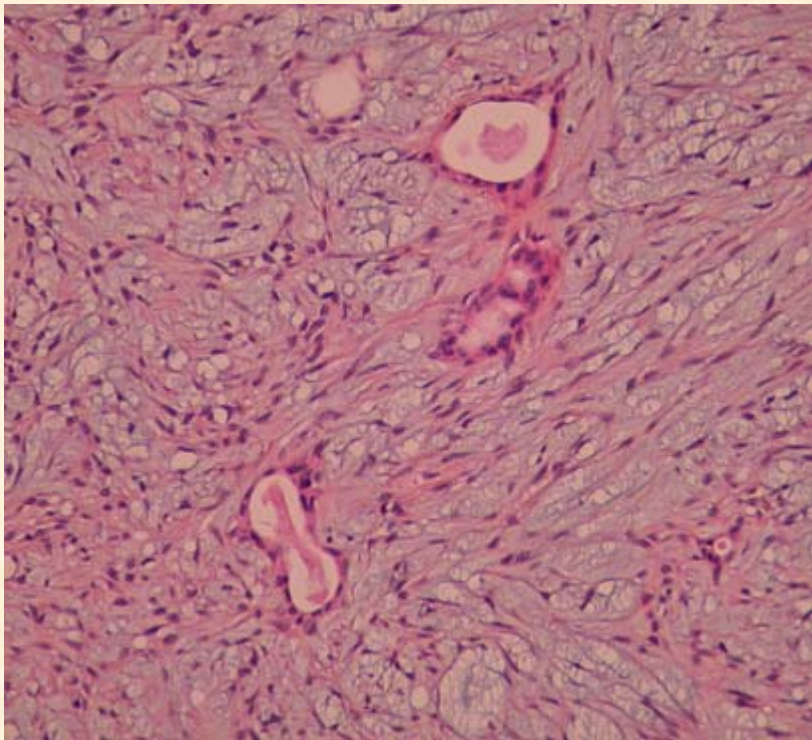
diagnostic proposé :

adénome pléomorphe à cellules fusiformes
prédominantes et lipomateux



09.8423

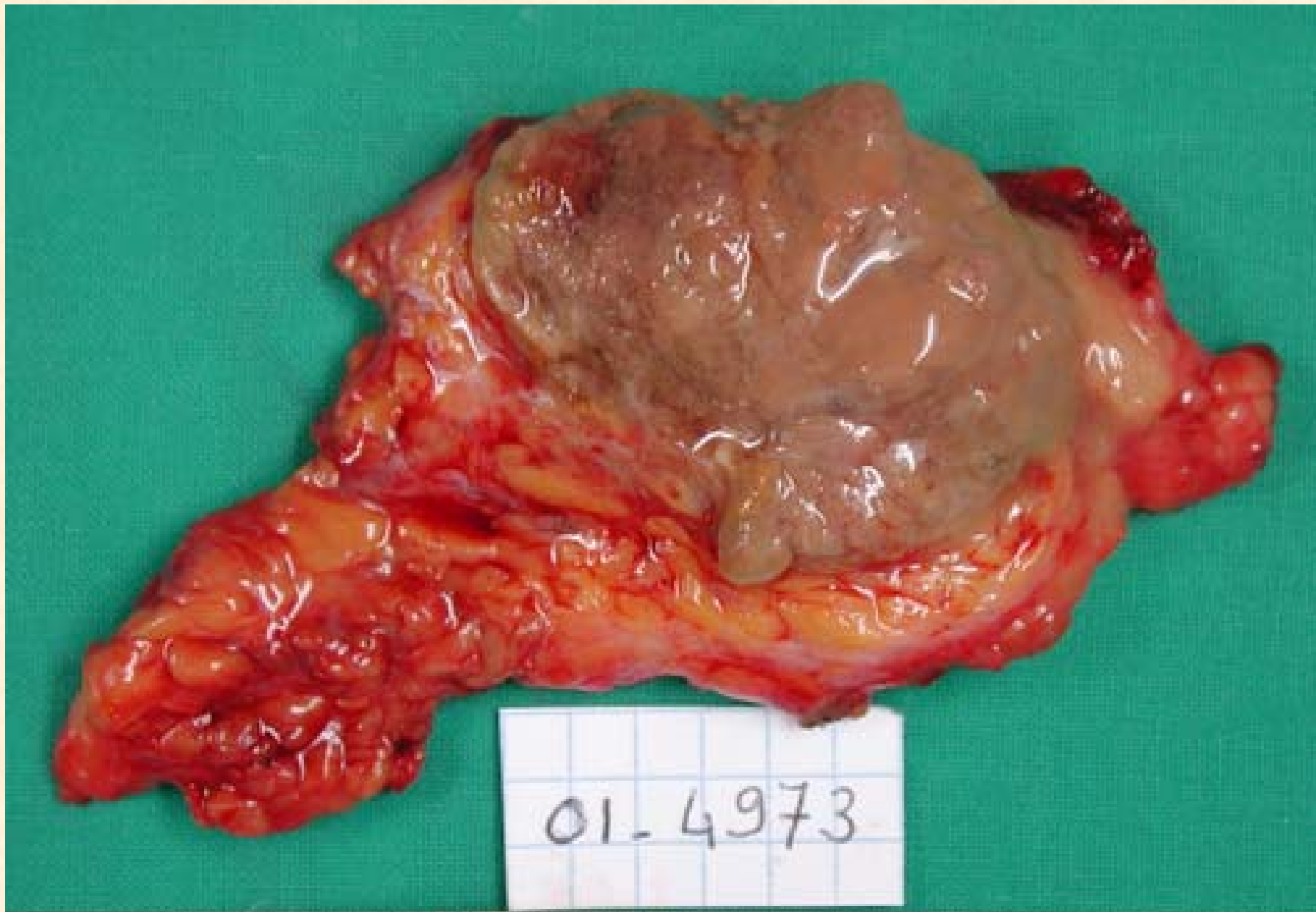



Cas n°2

diagnostic proposé :

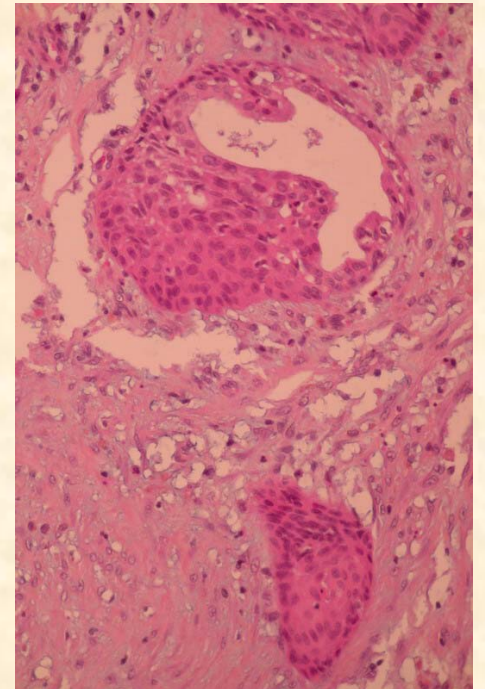
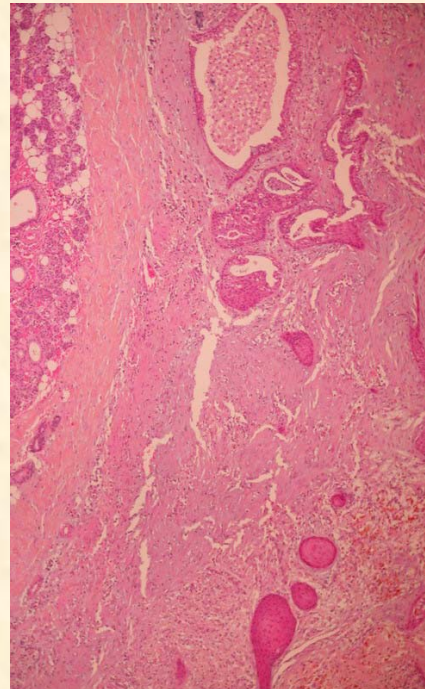
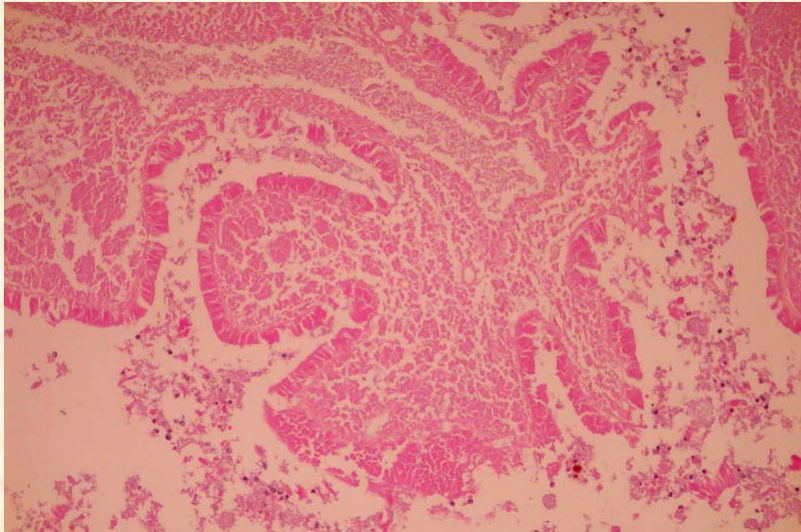
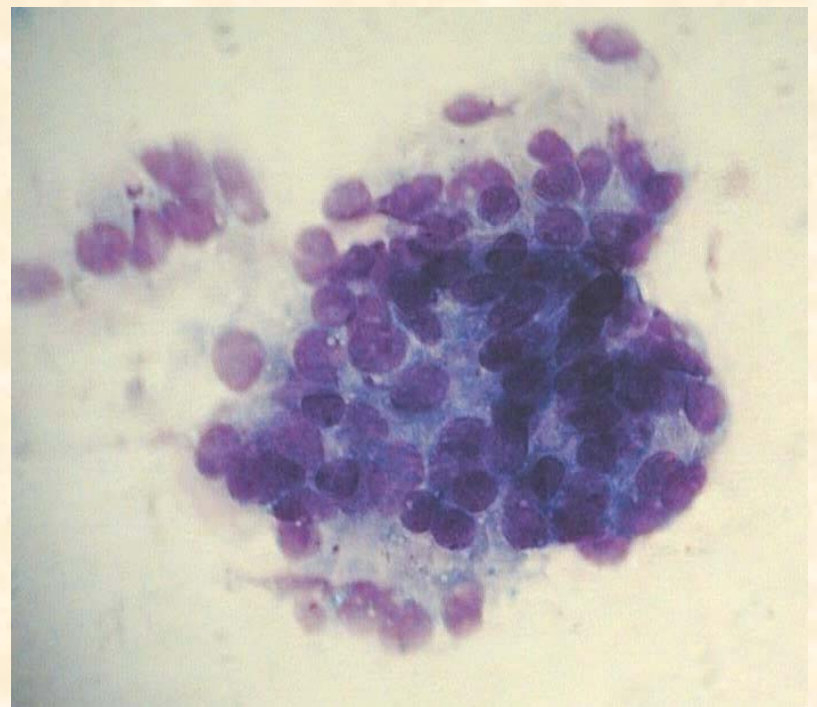
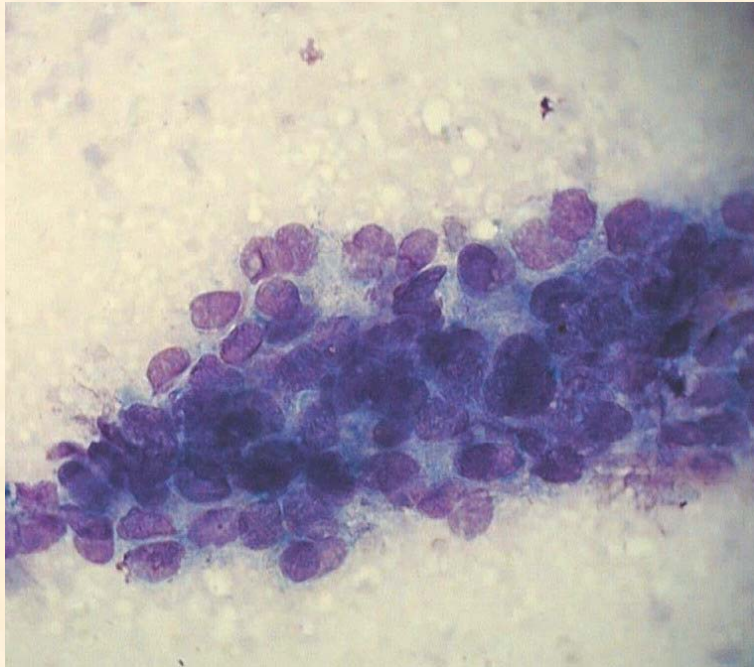
tumeur de Warthin remaniée, avec métaplasie malpighienne et dystrophies cellulaires



01-4973



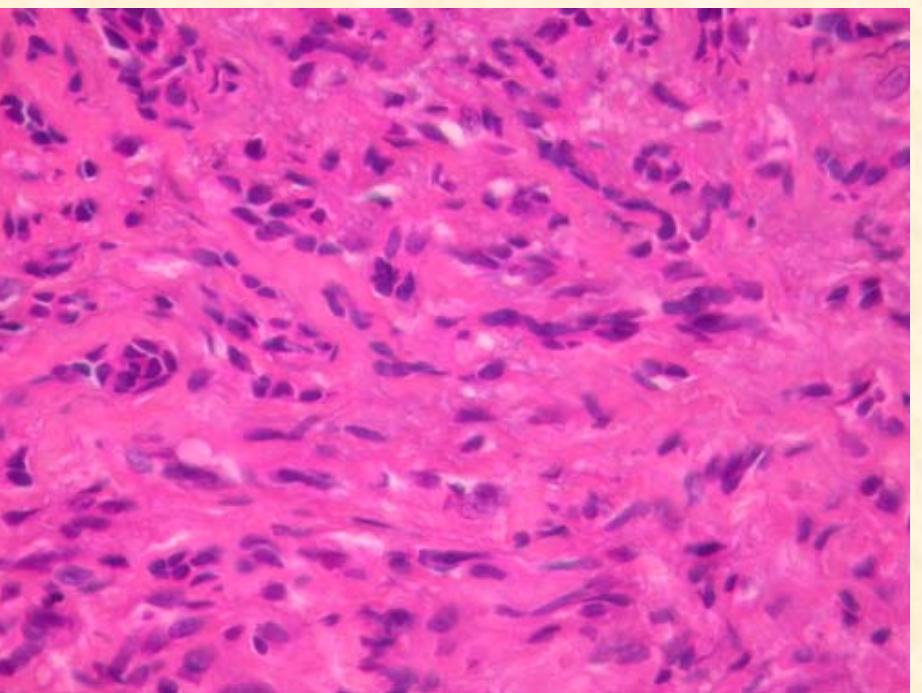
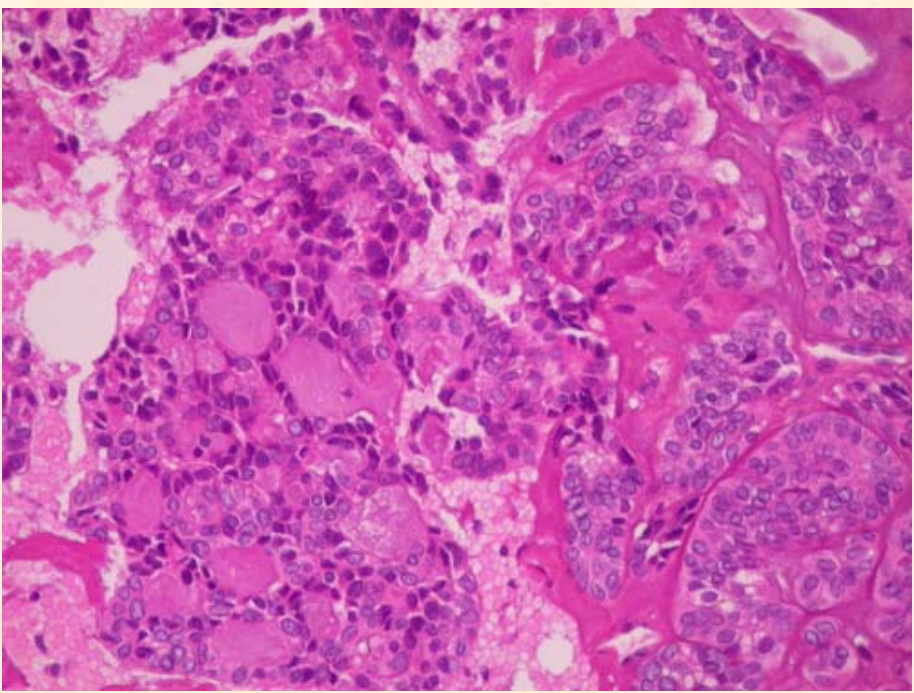
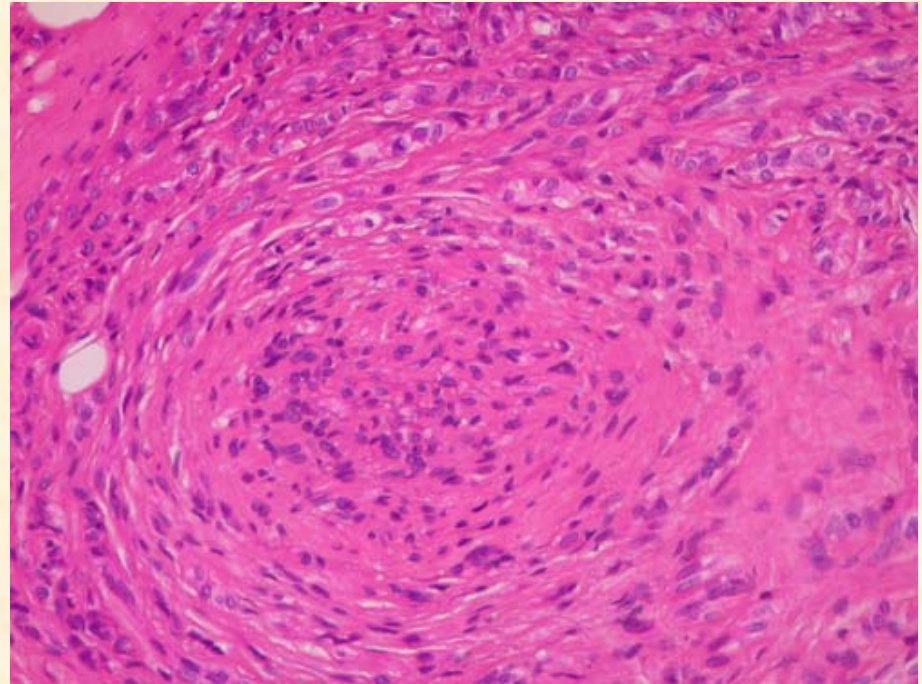
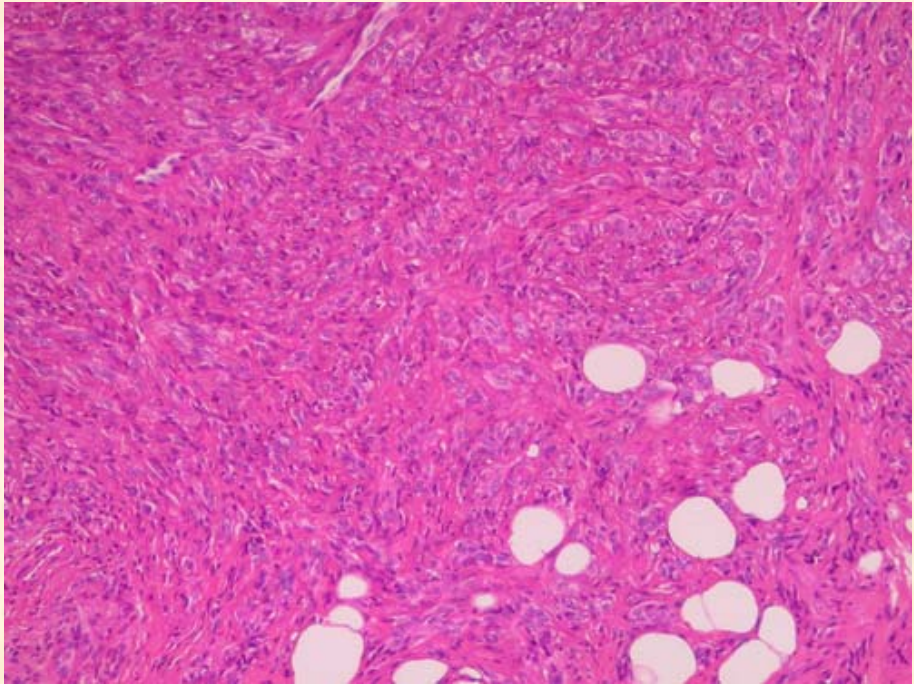
Warthin remanié métaplasie malpighienne



Cas n°3

diagnostic proposé :

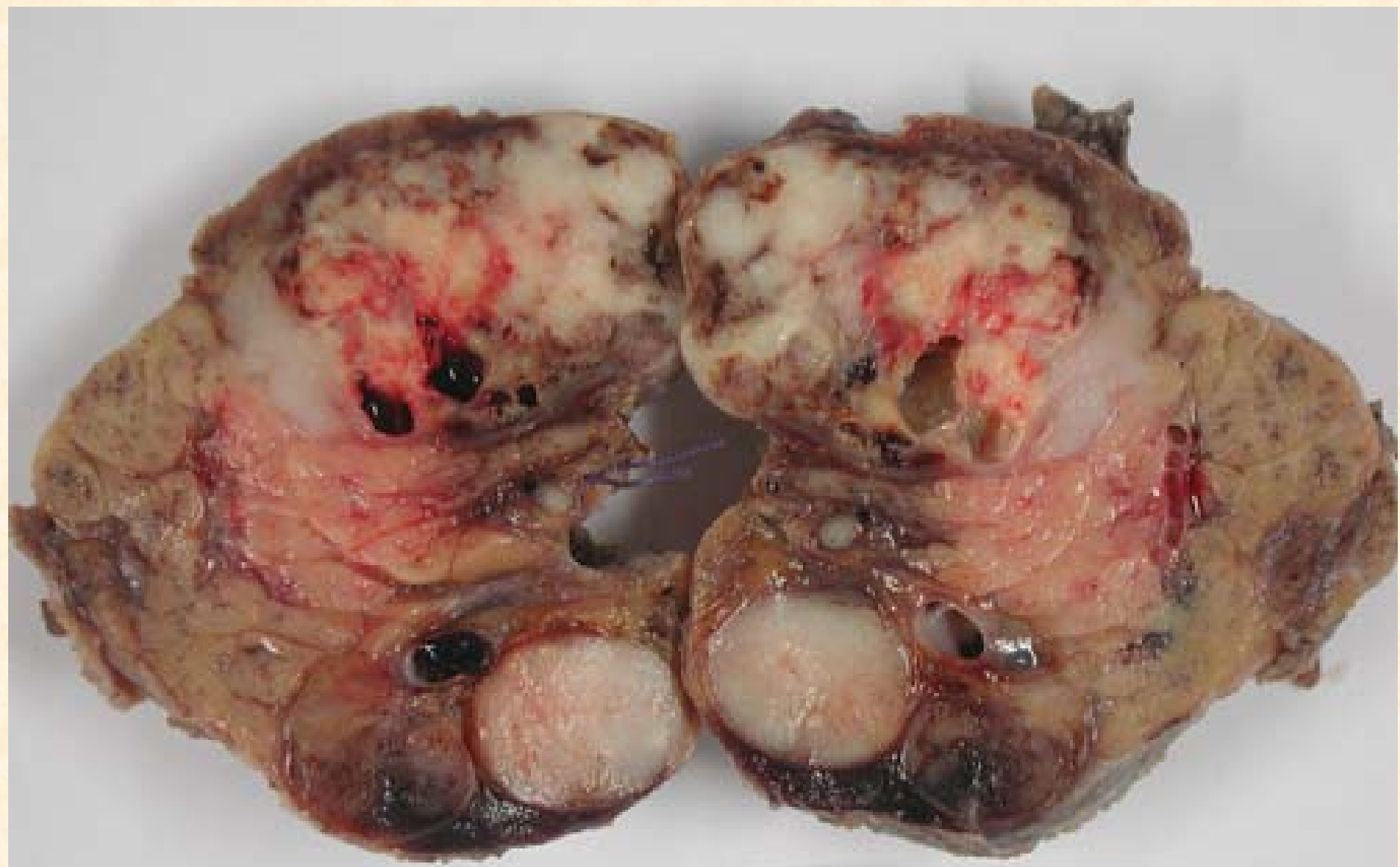adénocarcinome polymorphe de bas grade



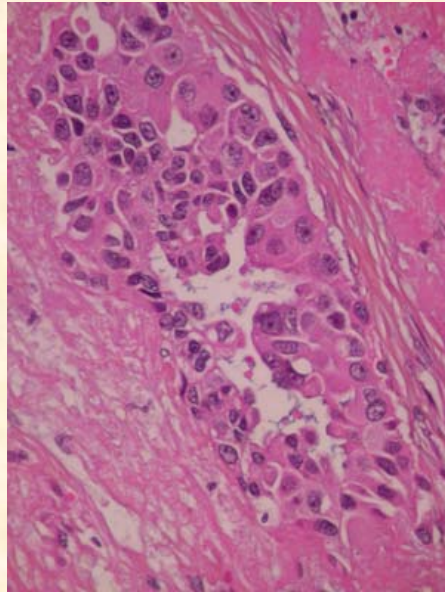
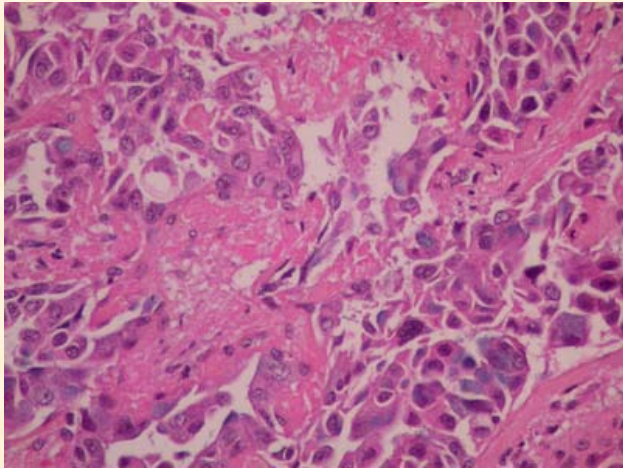
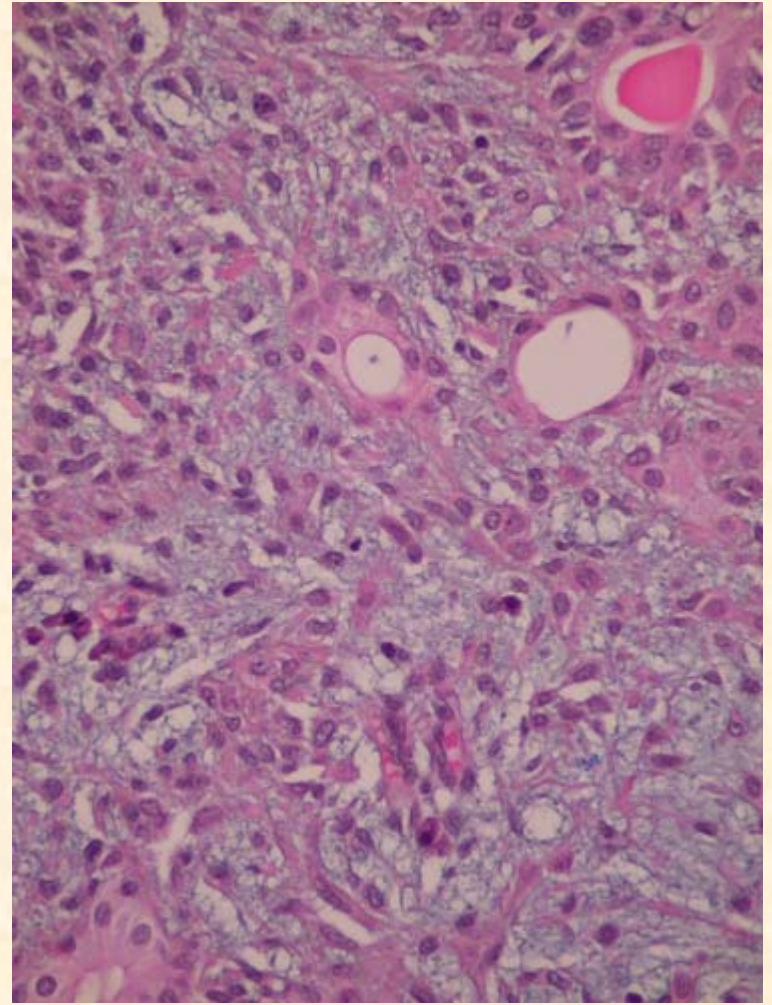
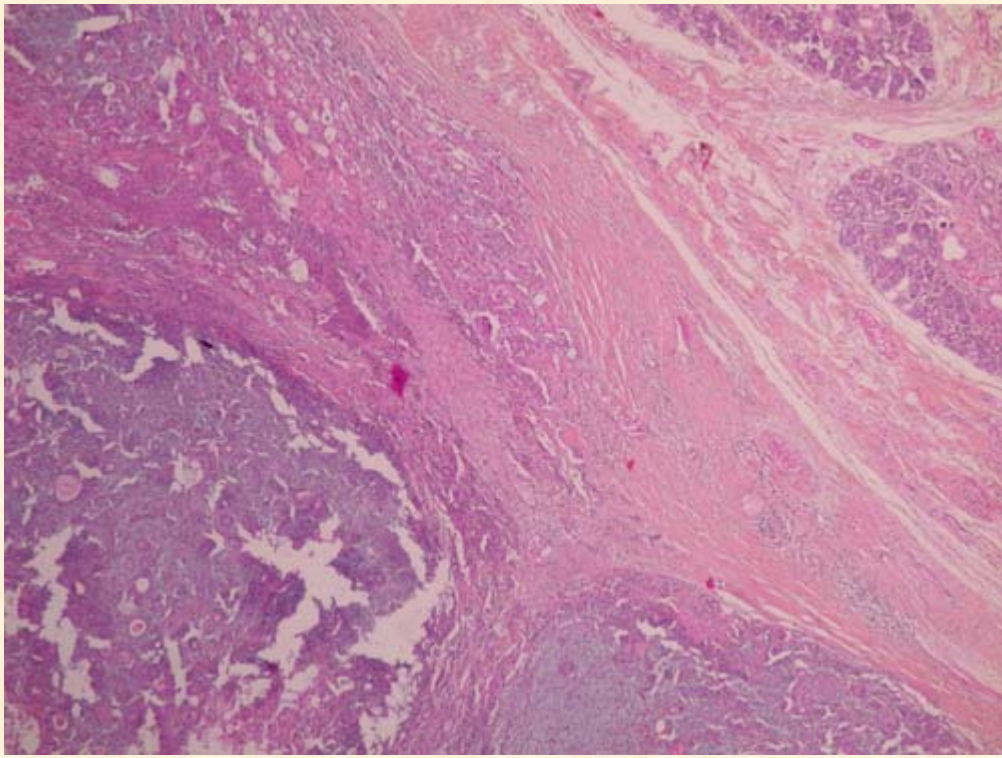
Cas n°4

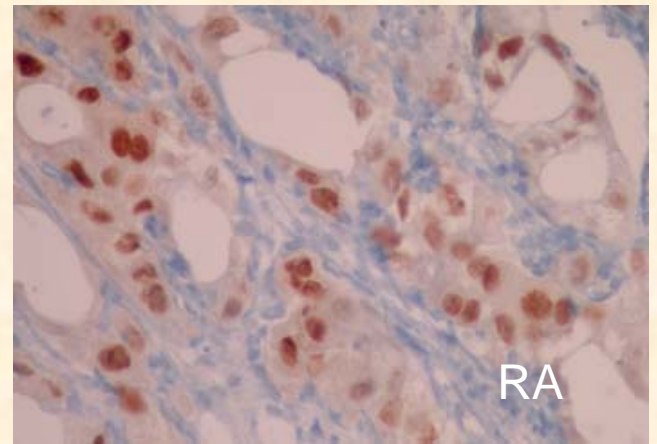
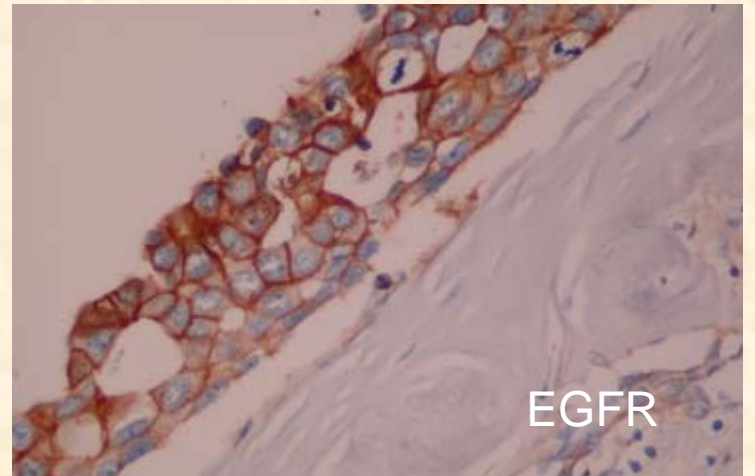
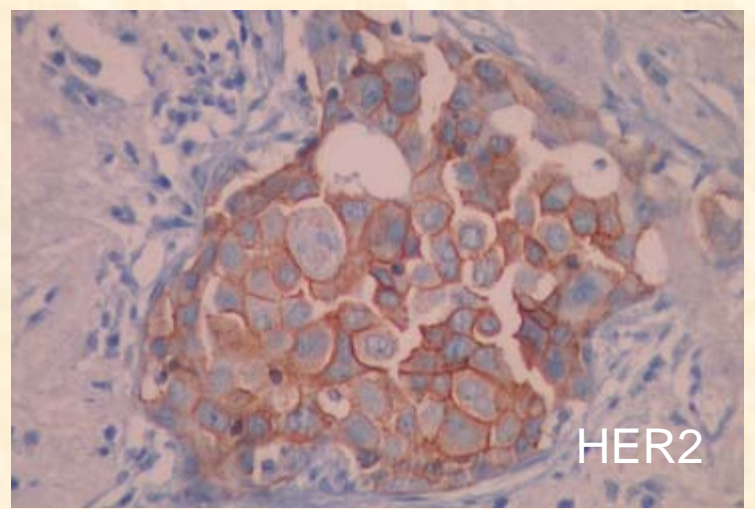
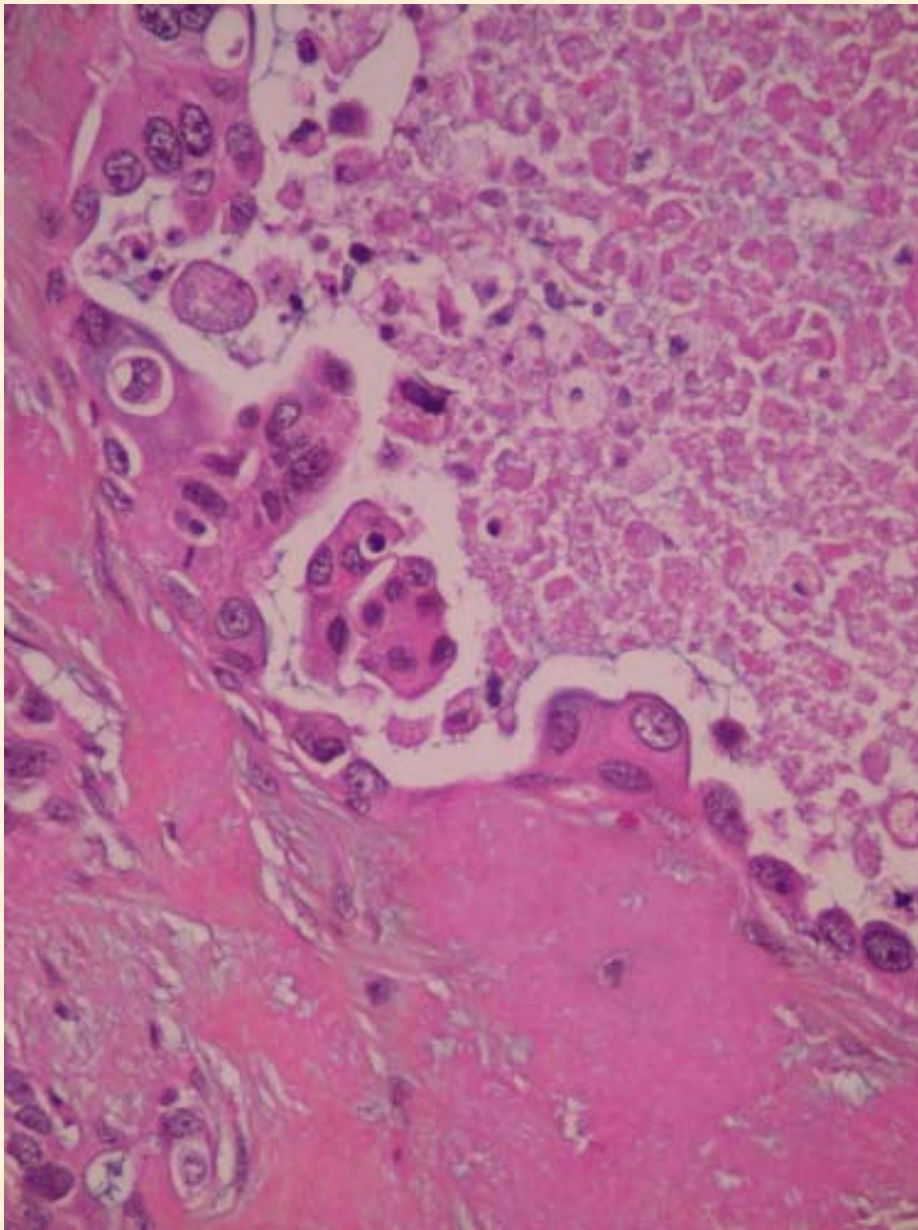
diagnostic proposé :

adénocarcinome primitif de haut grade avec
secteurs de type canalaire sur adénome
pléomorphe



09.7626

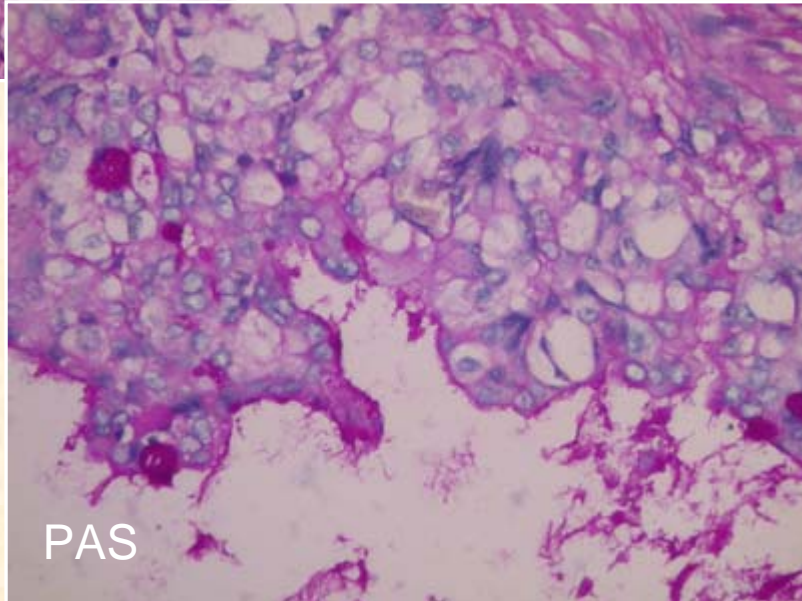
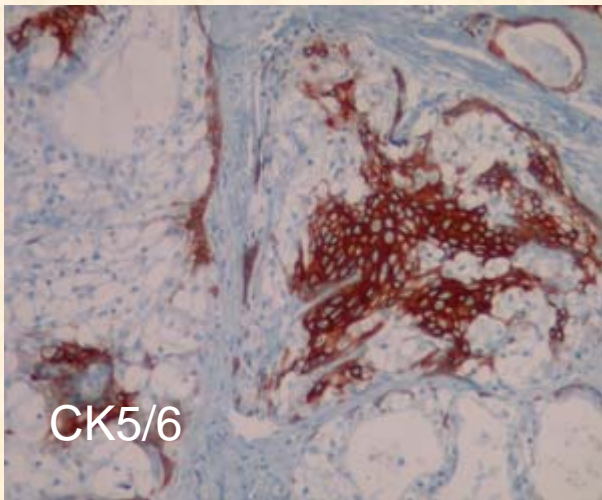
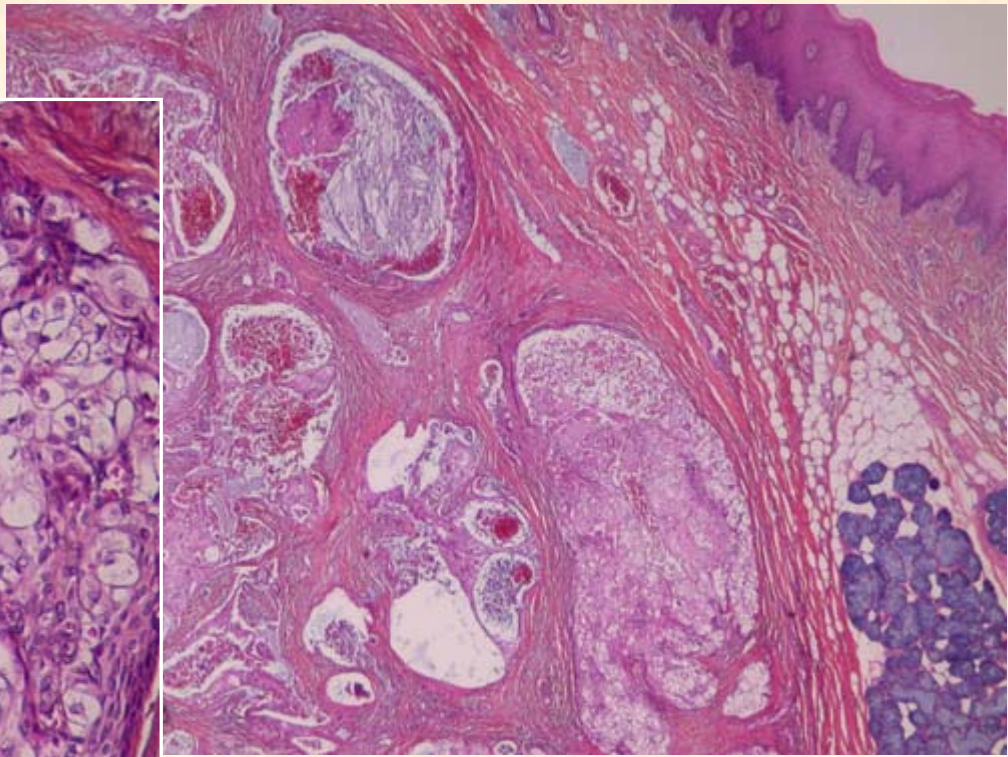
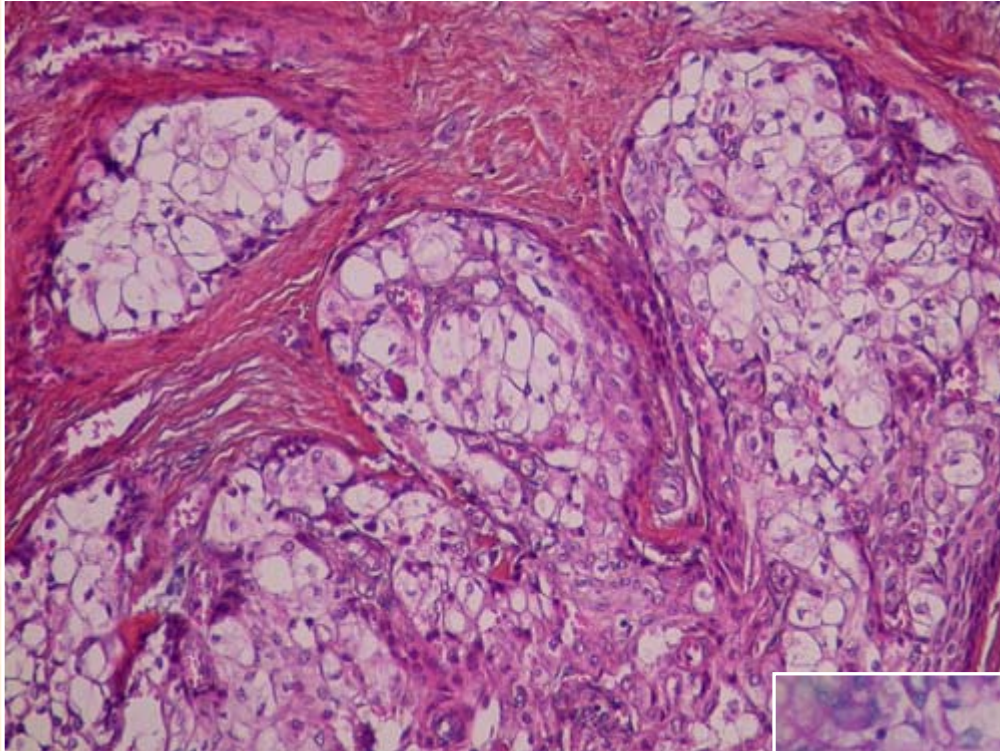




Cas n°5

diagnostic proposé :

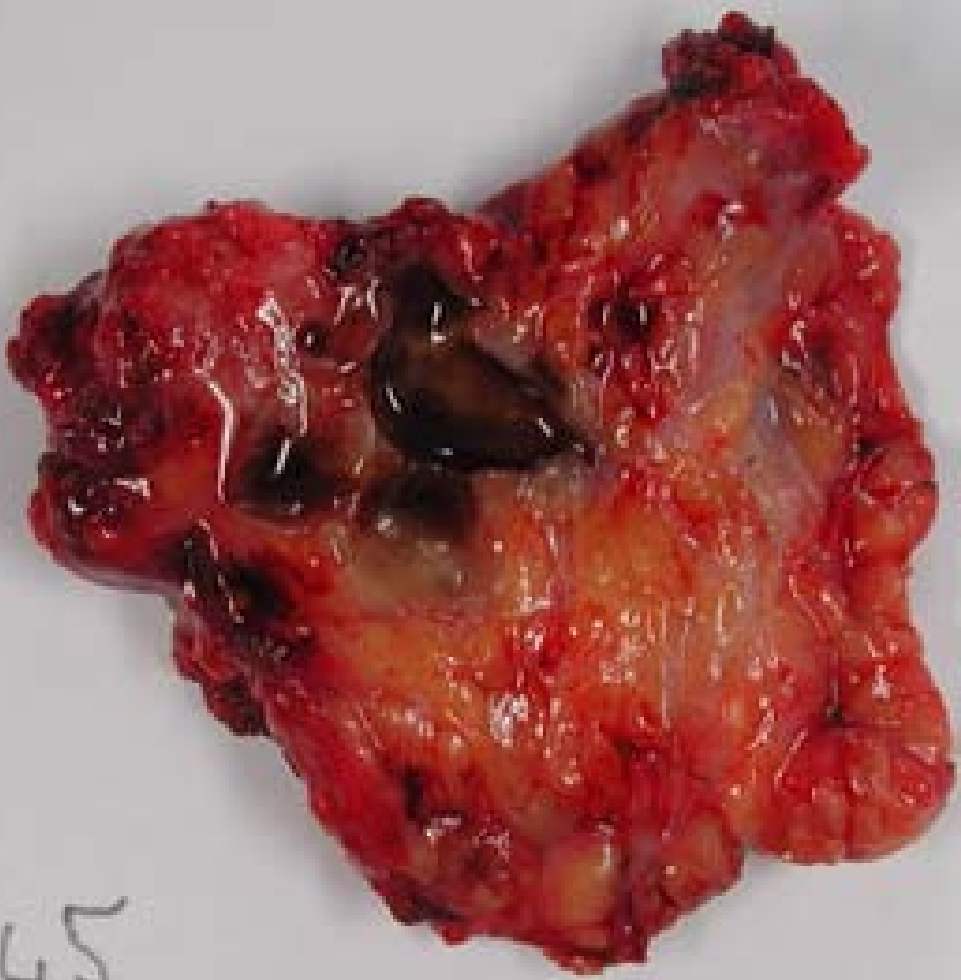
carcinome muco épidermoïde
à cellules claires, de bas grade




Cas n°6

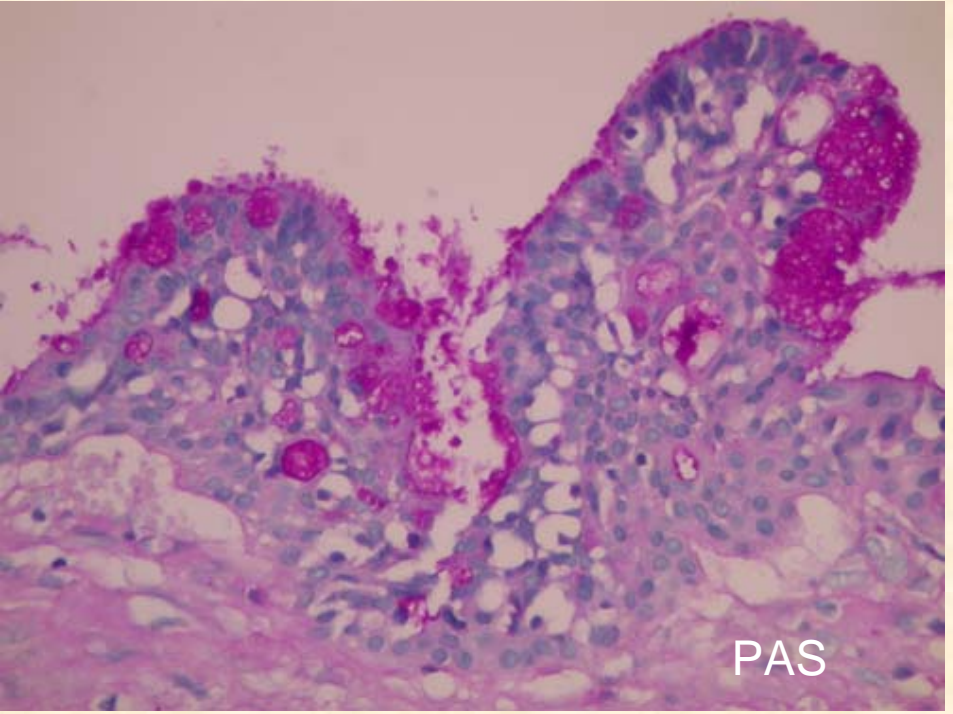
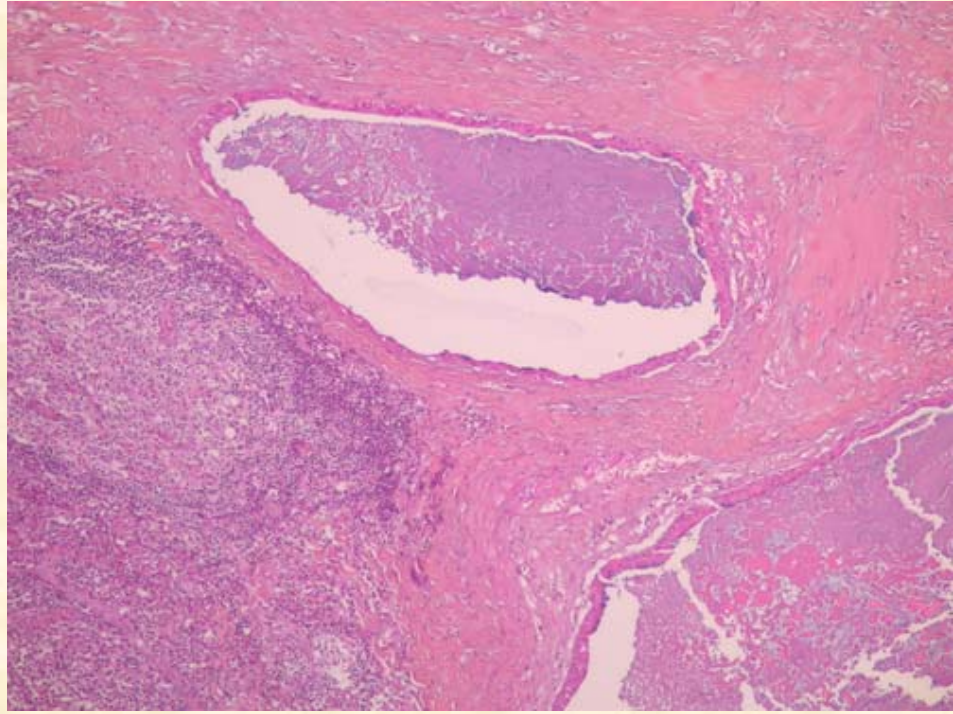
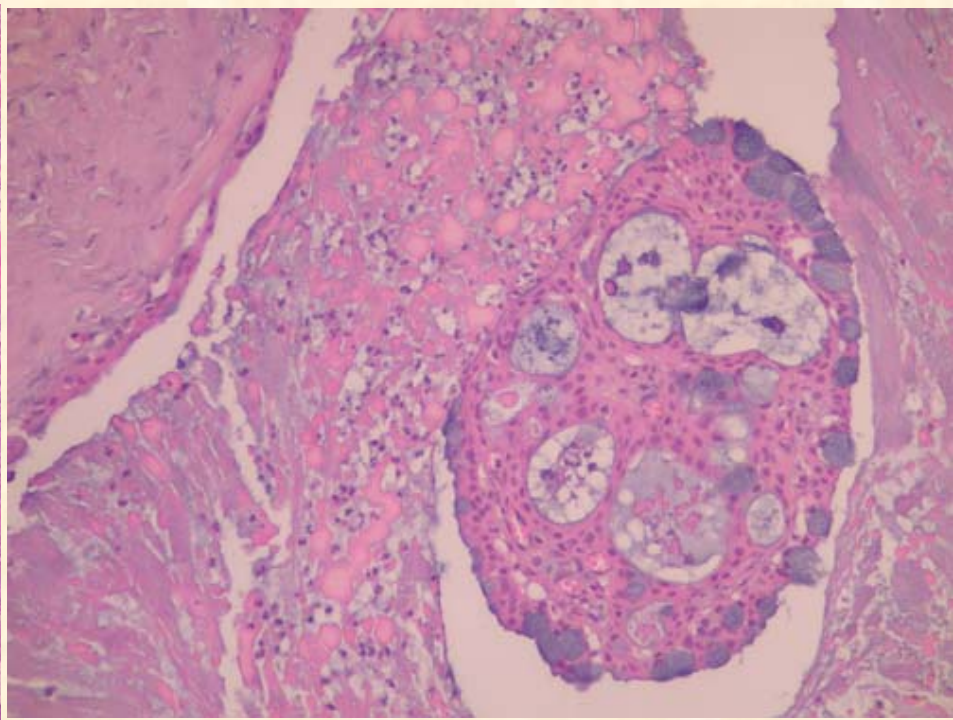
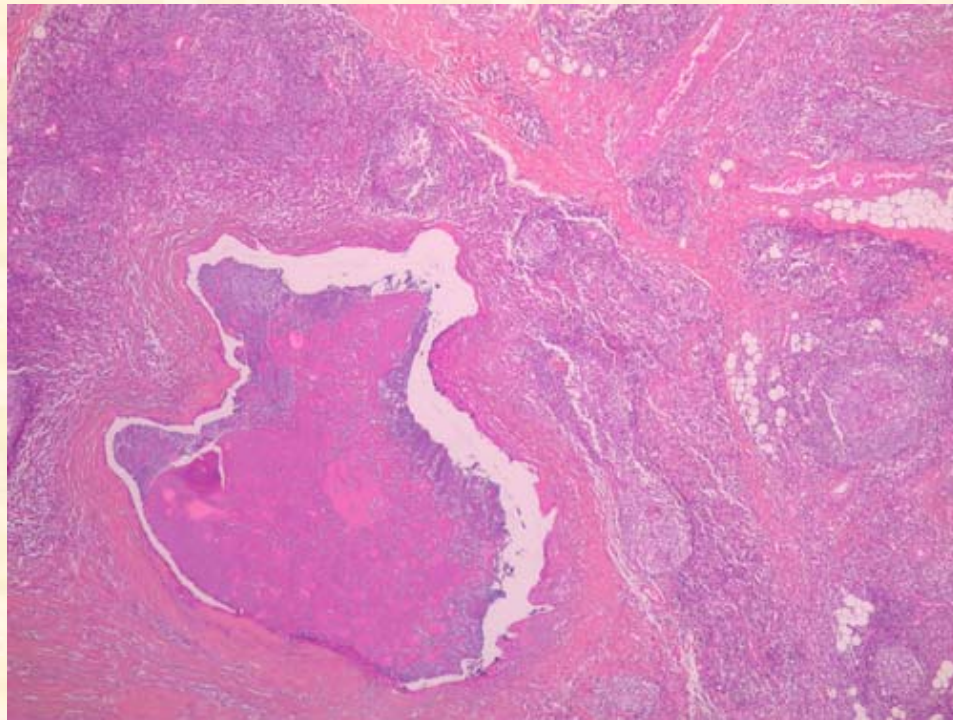
diagnostic proposé :

carcinome mucoépidermoïde de bas grade



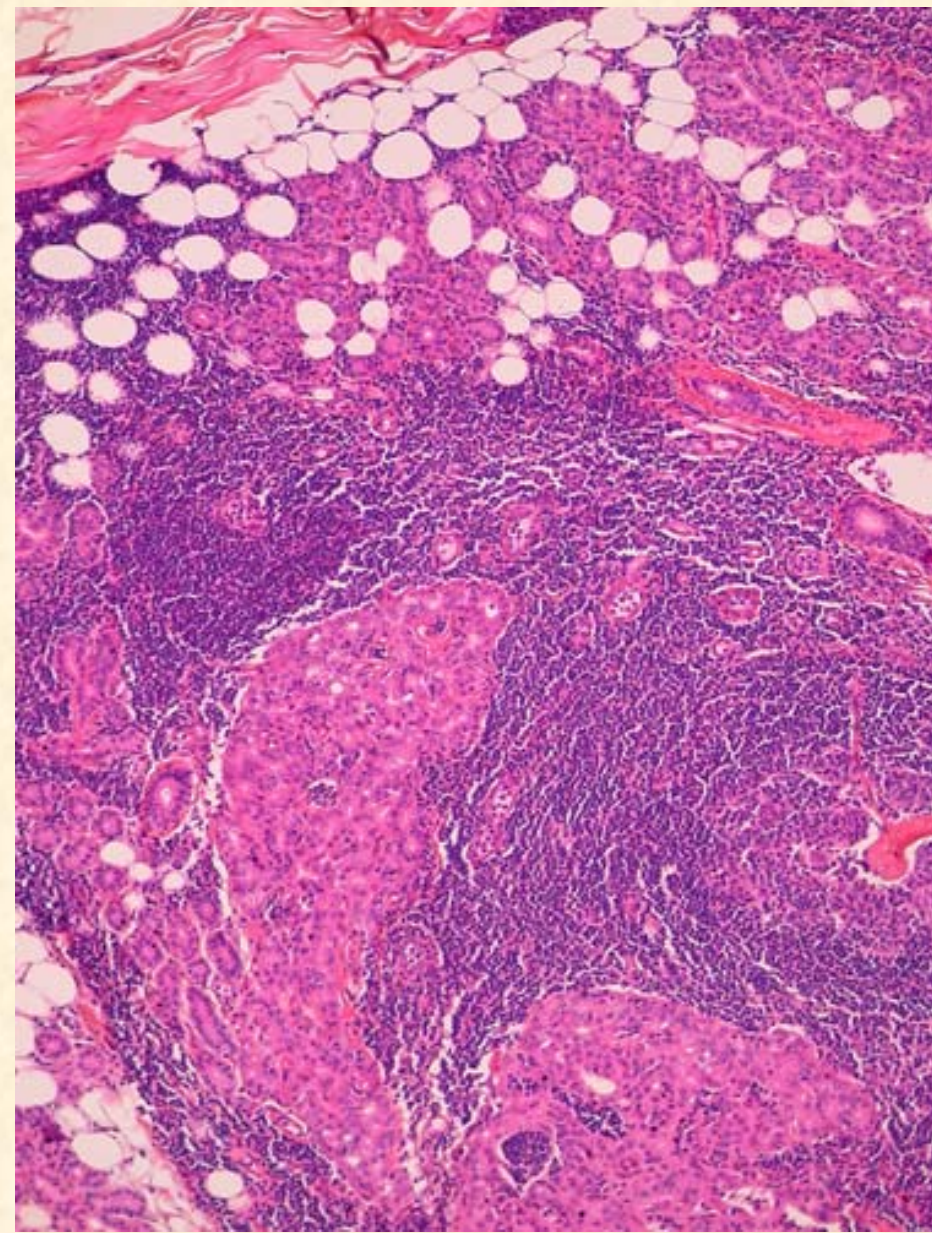
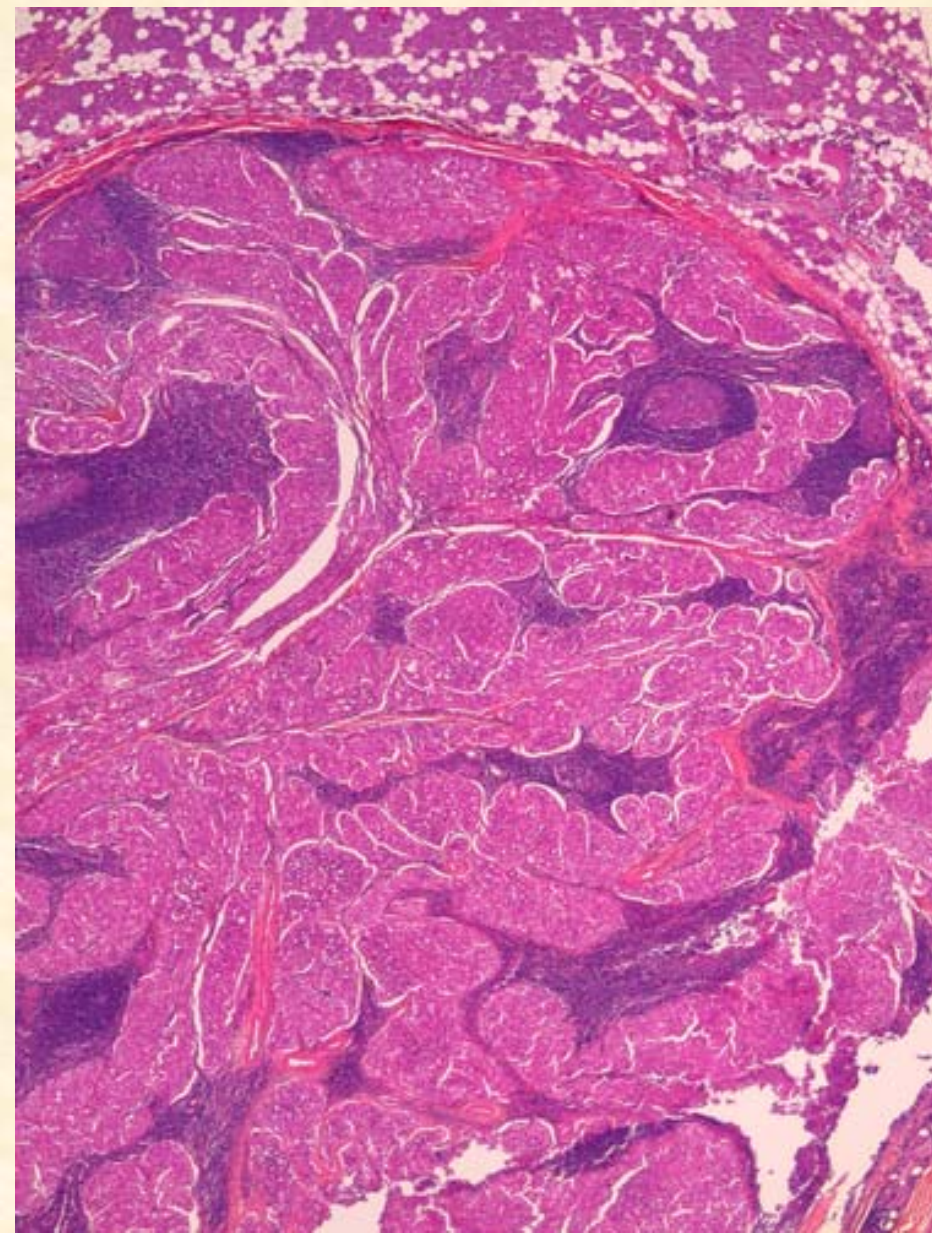
5408 F0

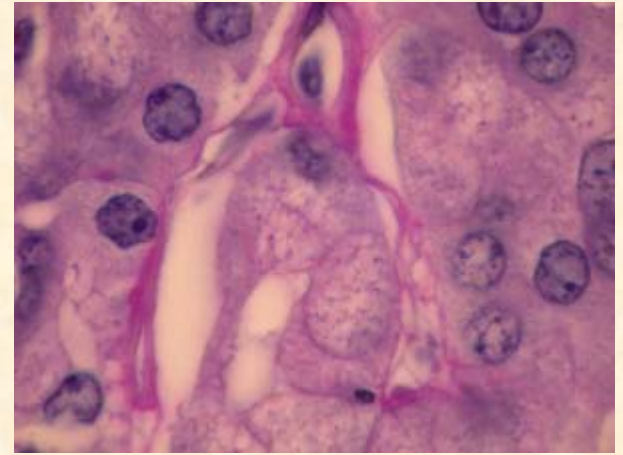
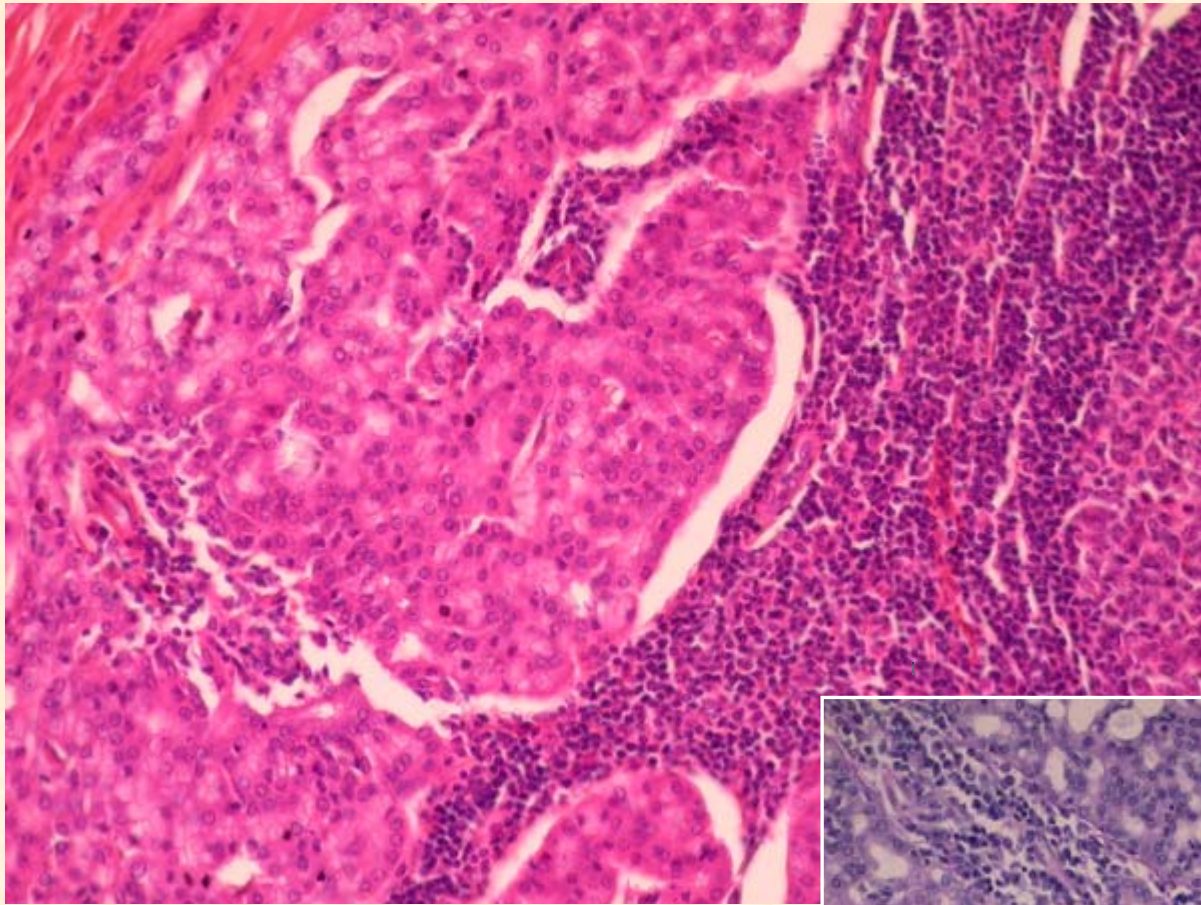




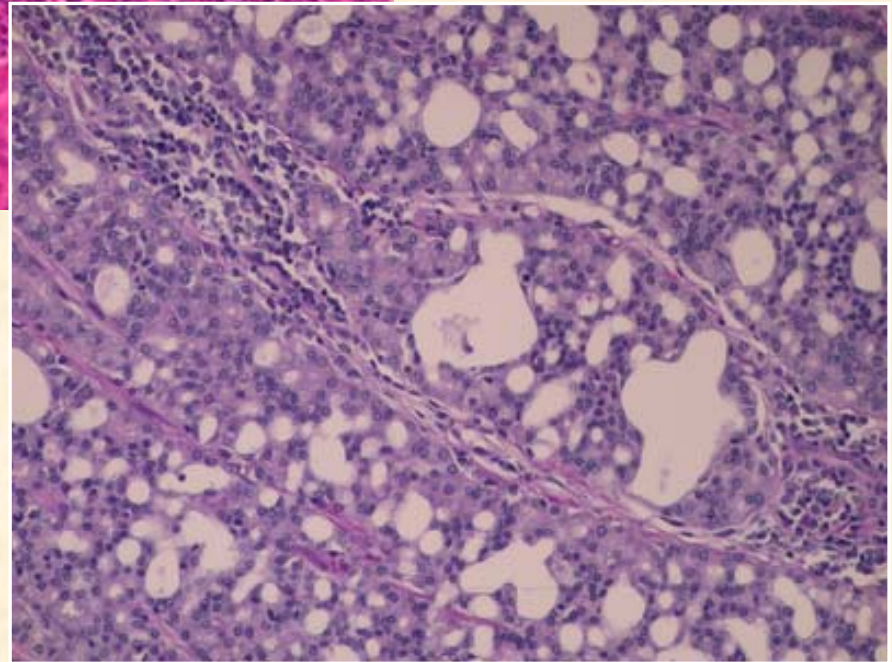
Cas n°7

diagnostic proposé :
adénocarcinome à cellules acineuses,
à stroma lymphoïde





PAS D

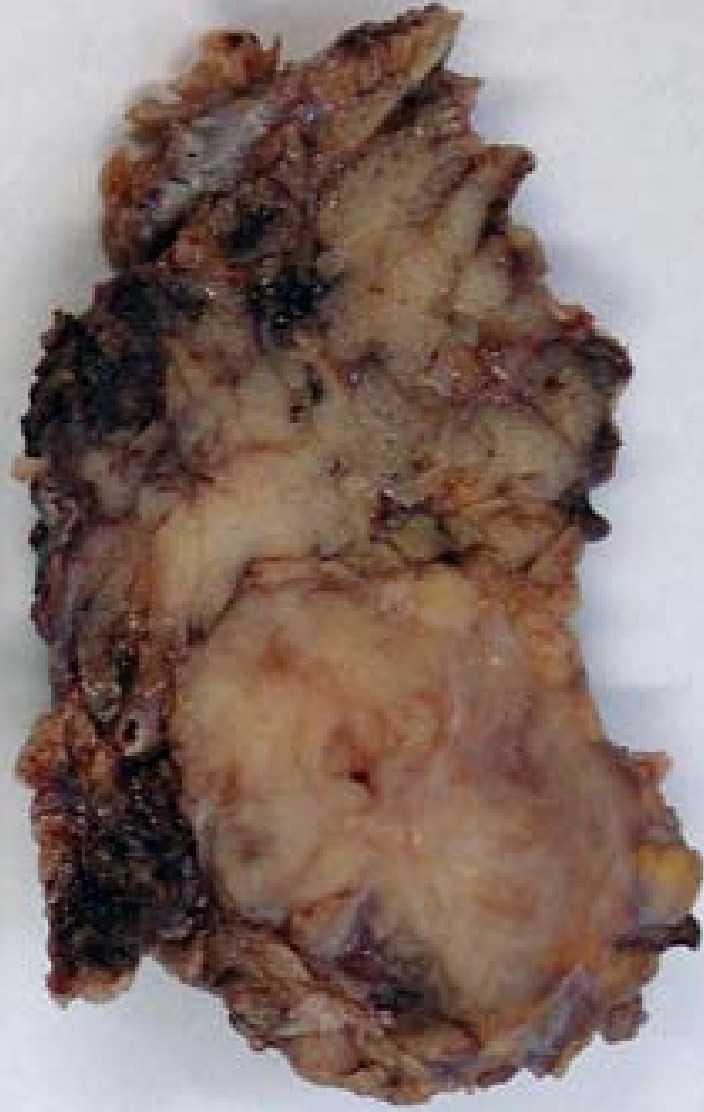
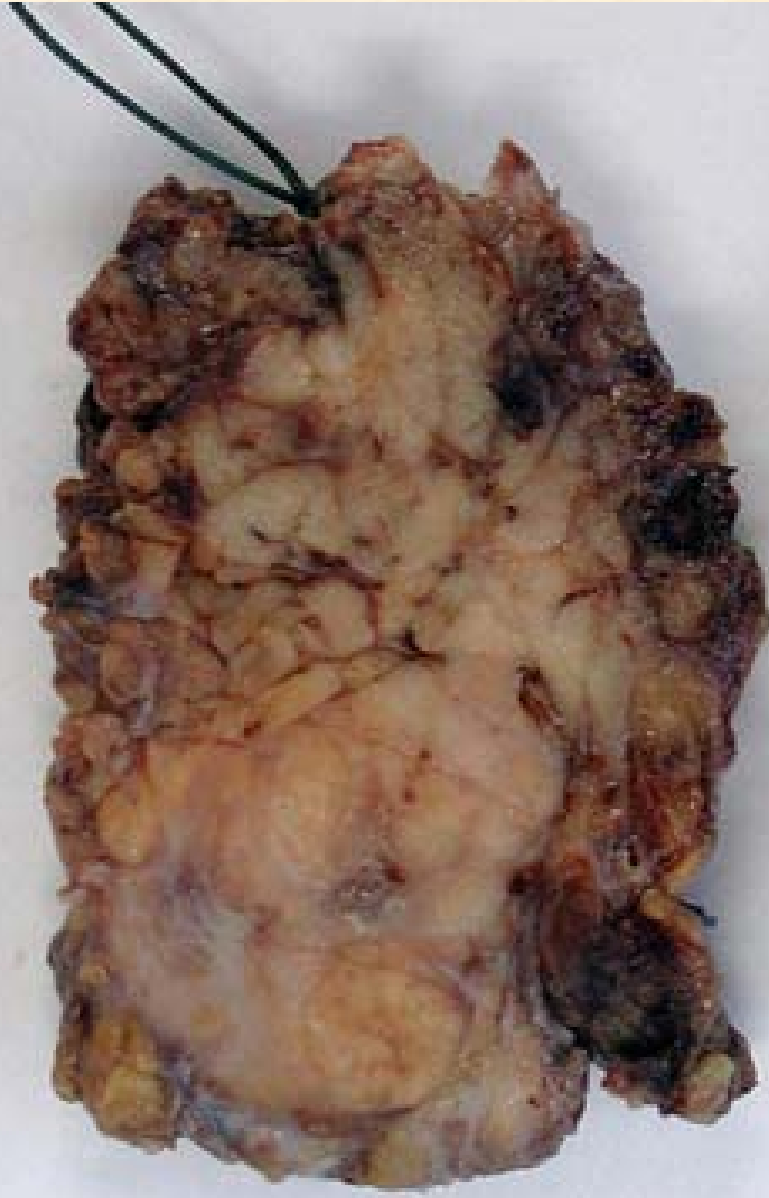
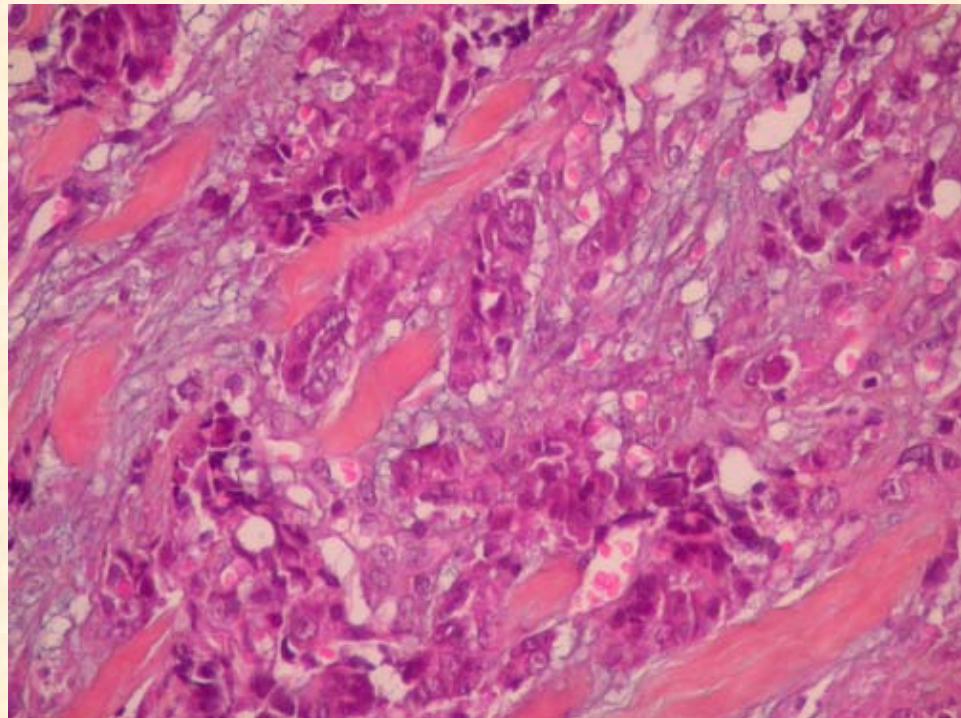
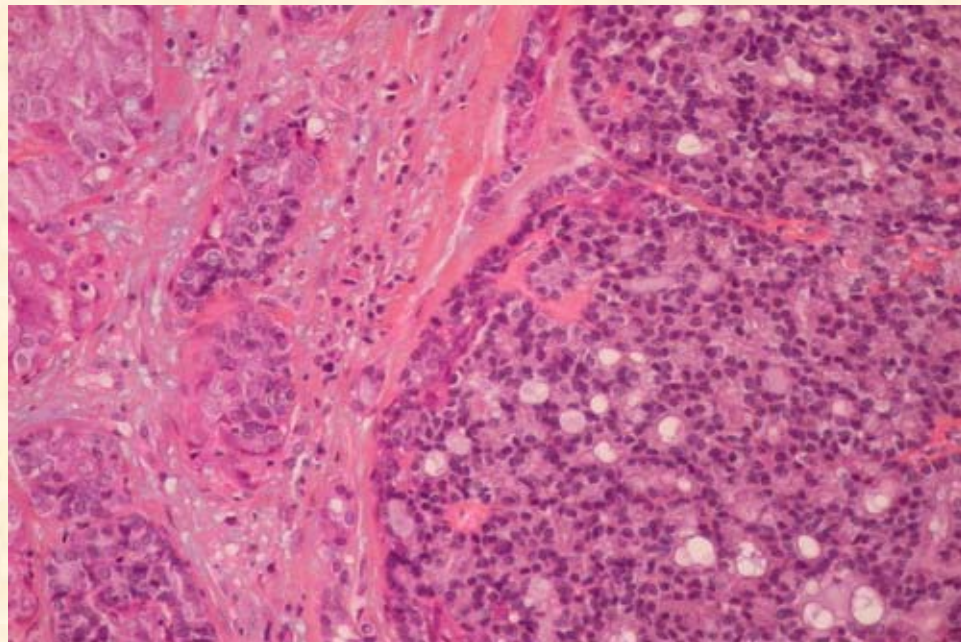
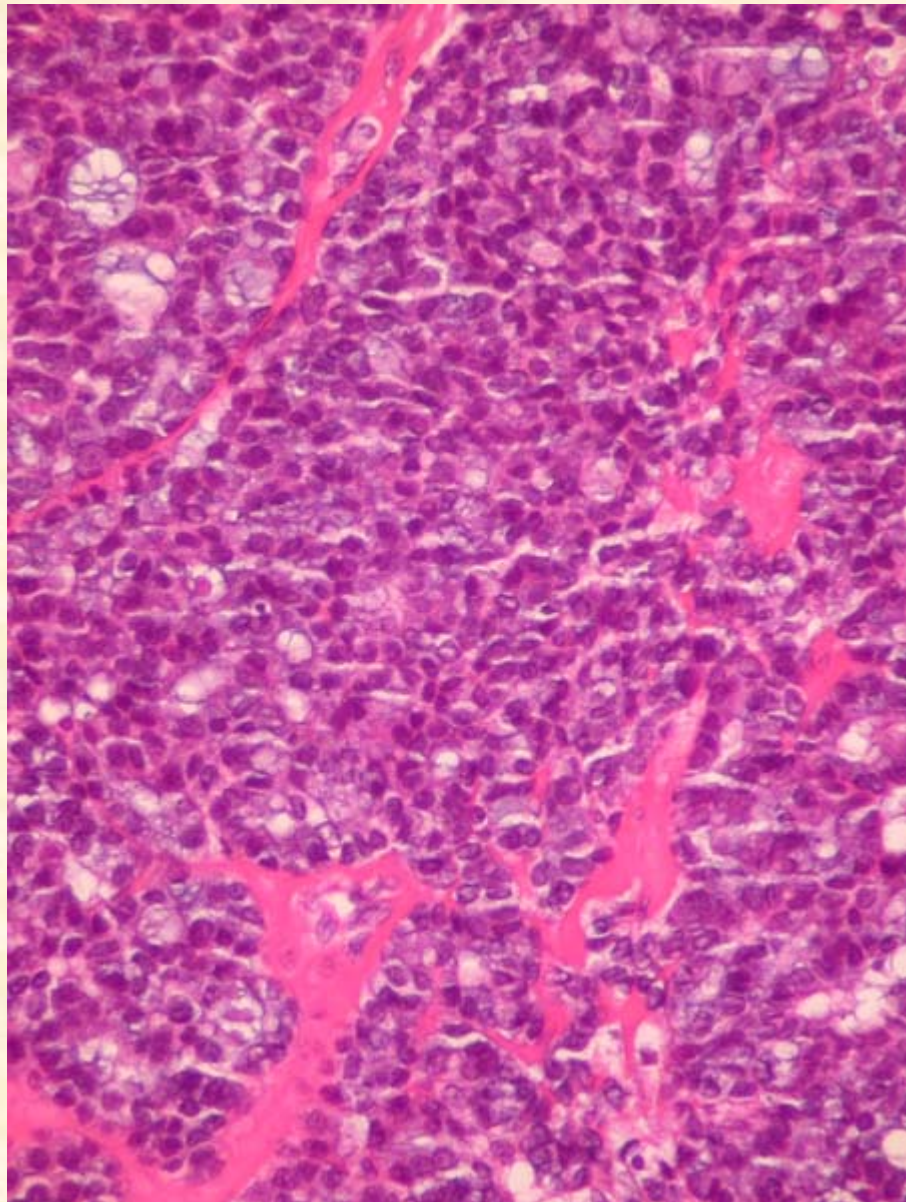
Cas n°8

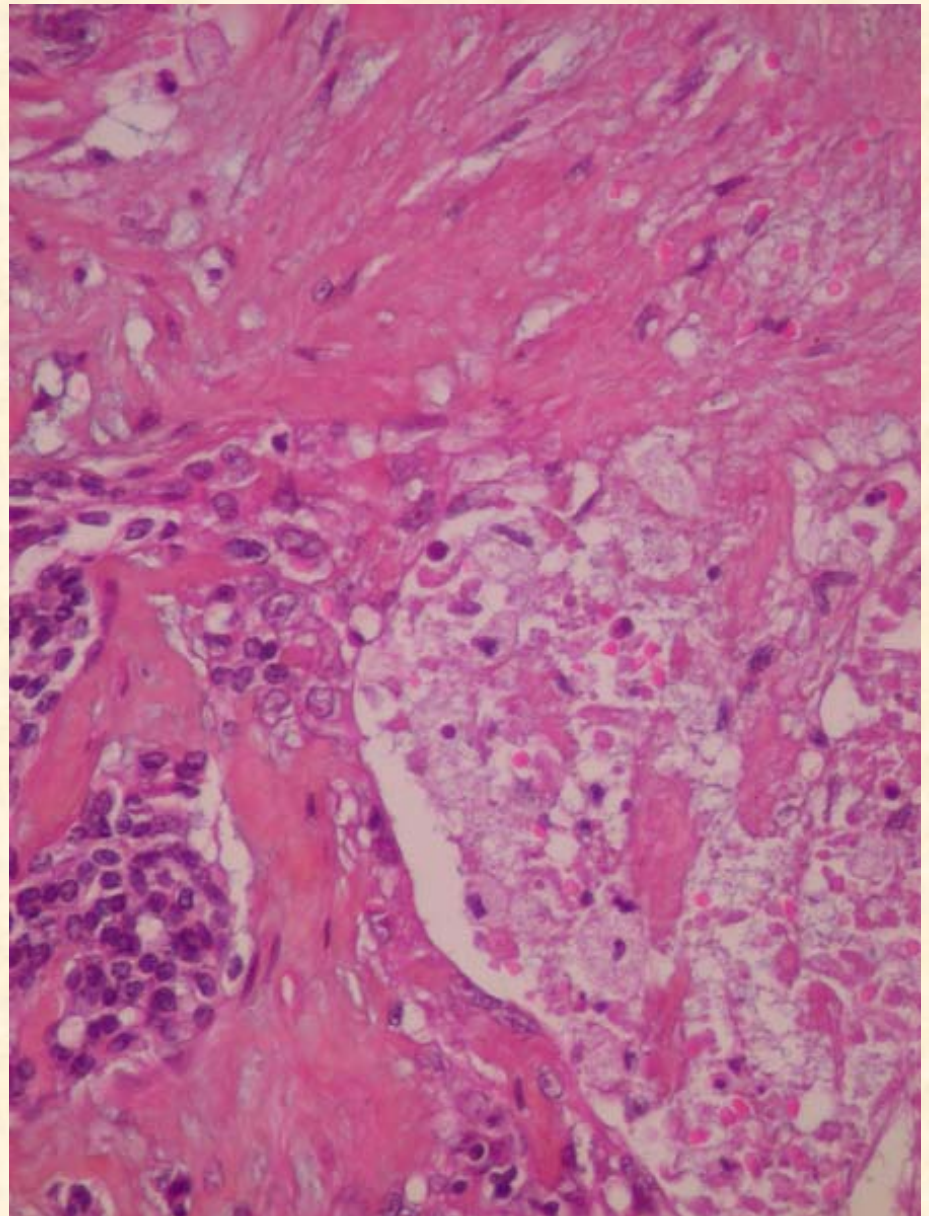
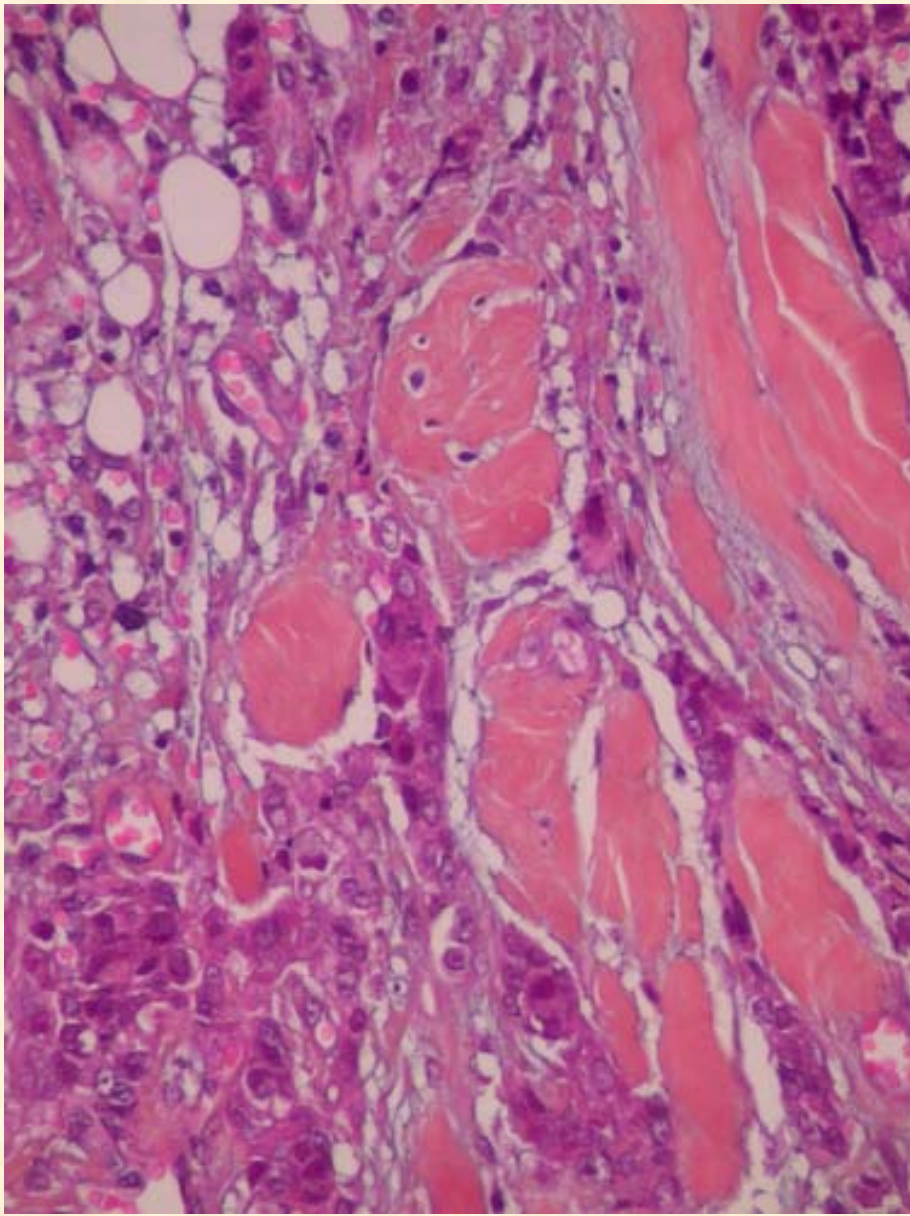
diagnostic proposé :

adénocarcinome à cellules acineuses,
avec contingent dédifférencié,
de haut grade

04 2184

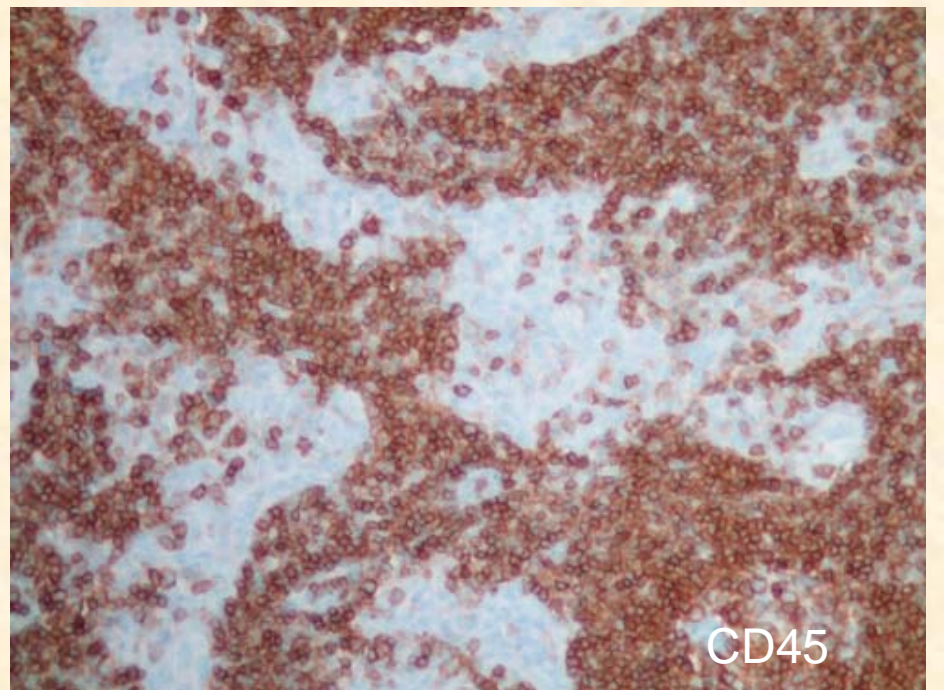
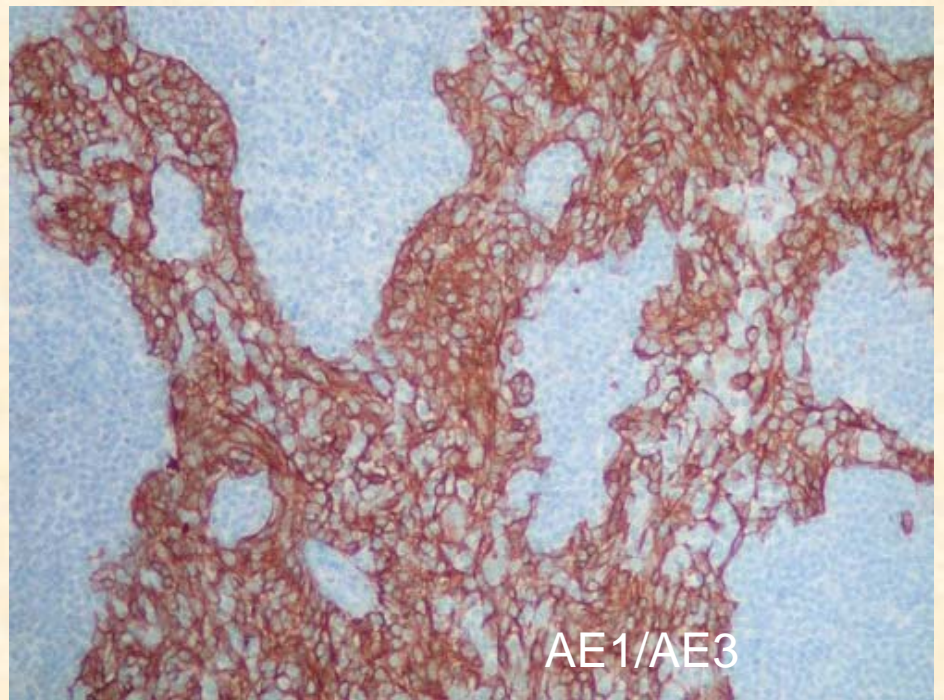
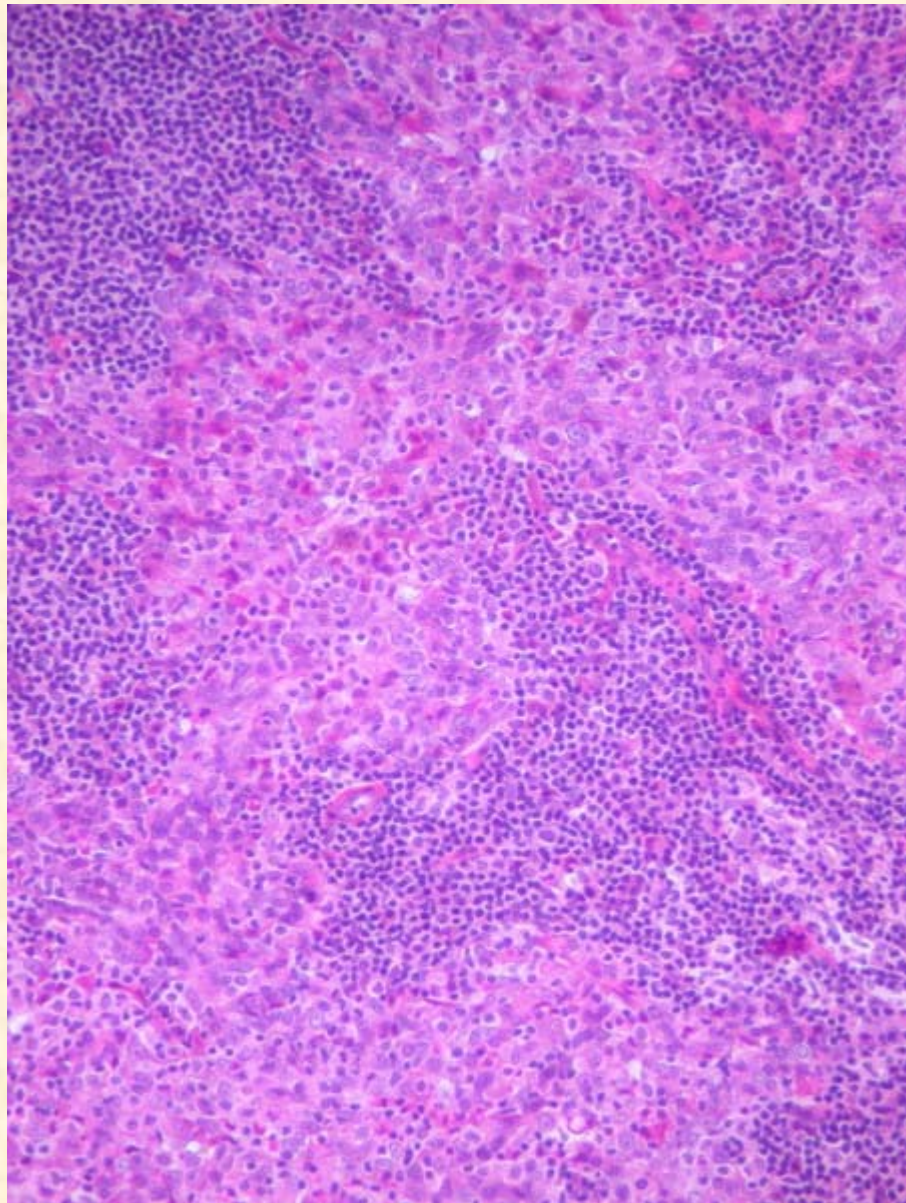






Cas n°9

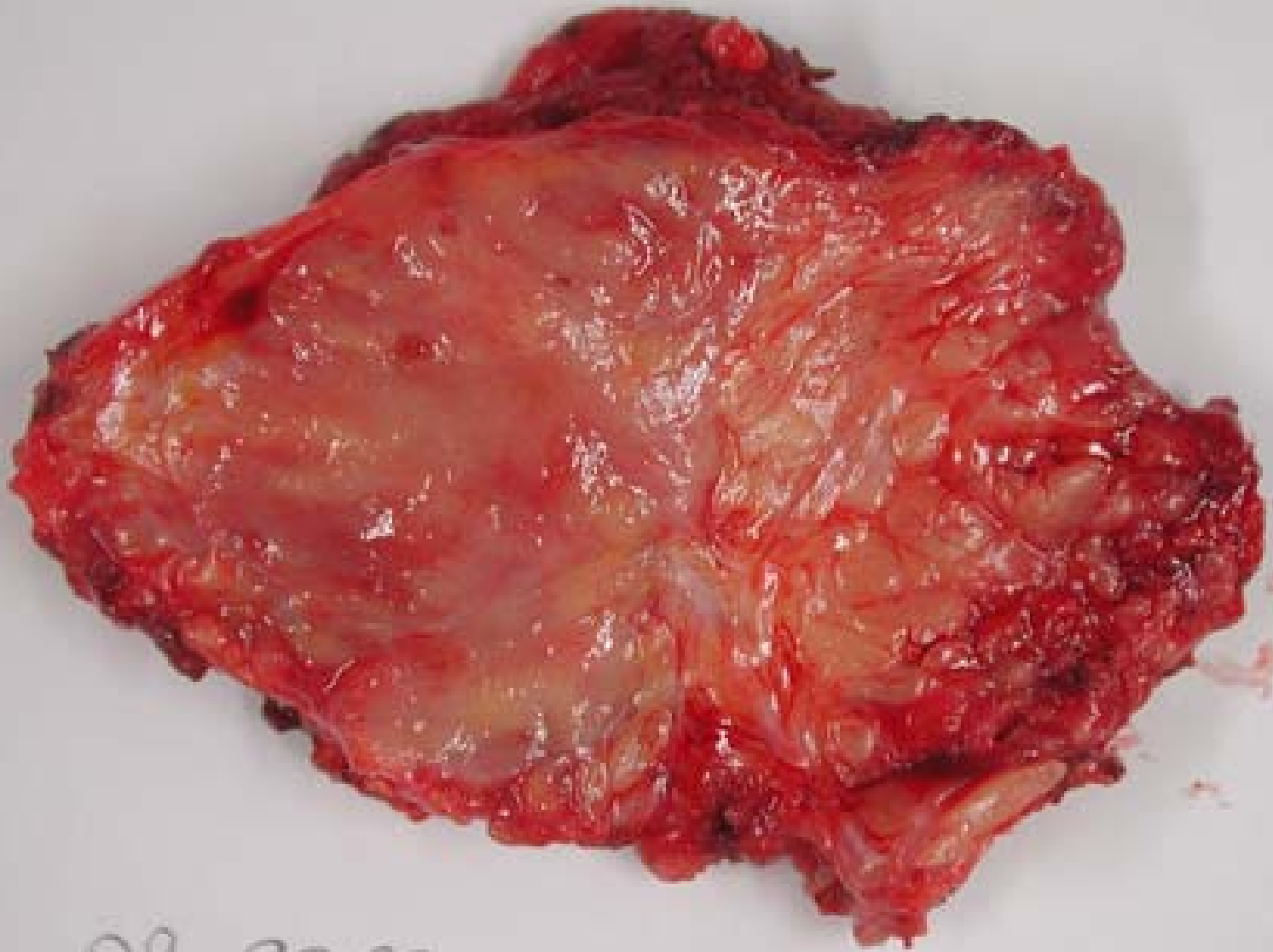
diagnostic proposé :
carcinome lympho épithélial



Cas n°10

diagnostic proposé :

métastase parotidienne d'un adénocarcinome
peu différencié (primitif pulmonaire)



09 9262



