

Cas clinique 10

Philippe Camparo
Hopital Foch, Suresnes
Bruxelles 14 mai 2011

Patient de 54 ans

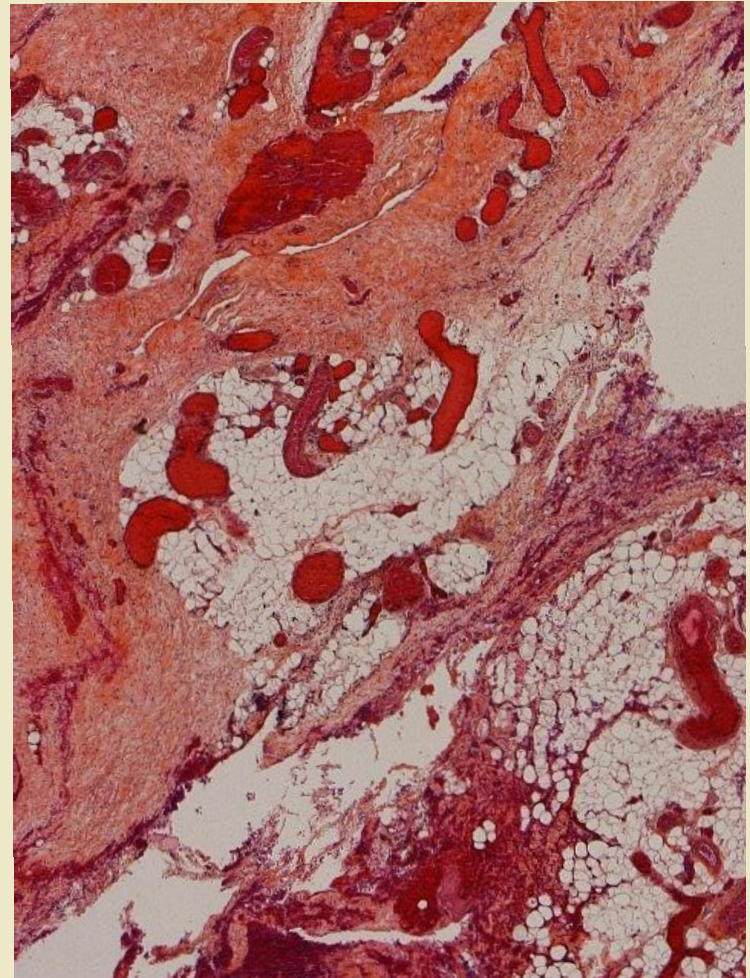
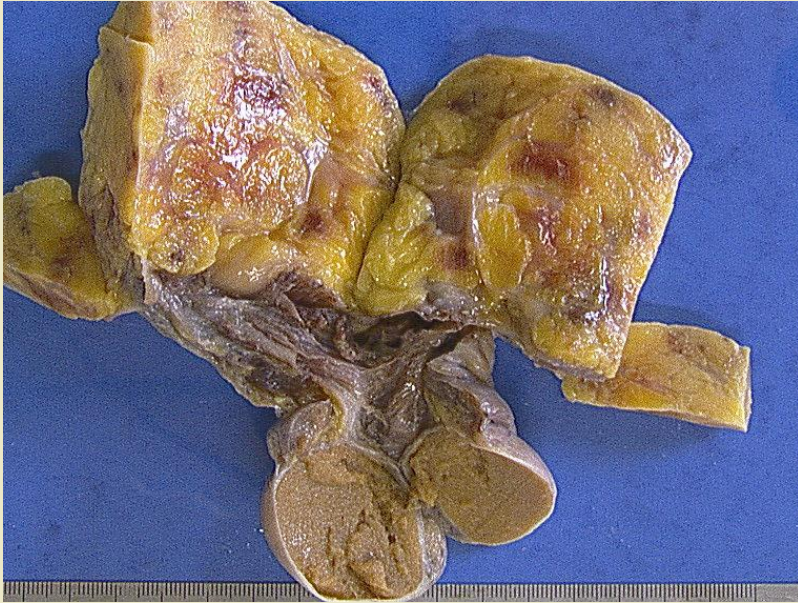
Masse paratesticulaire d'apparition récente

Diagnostic

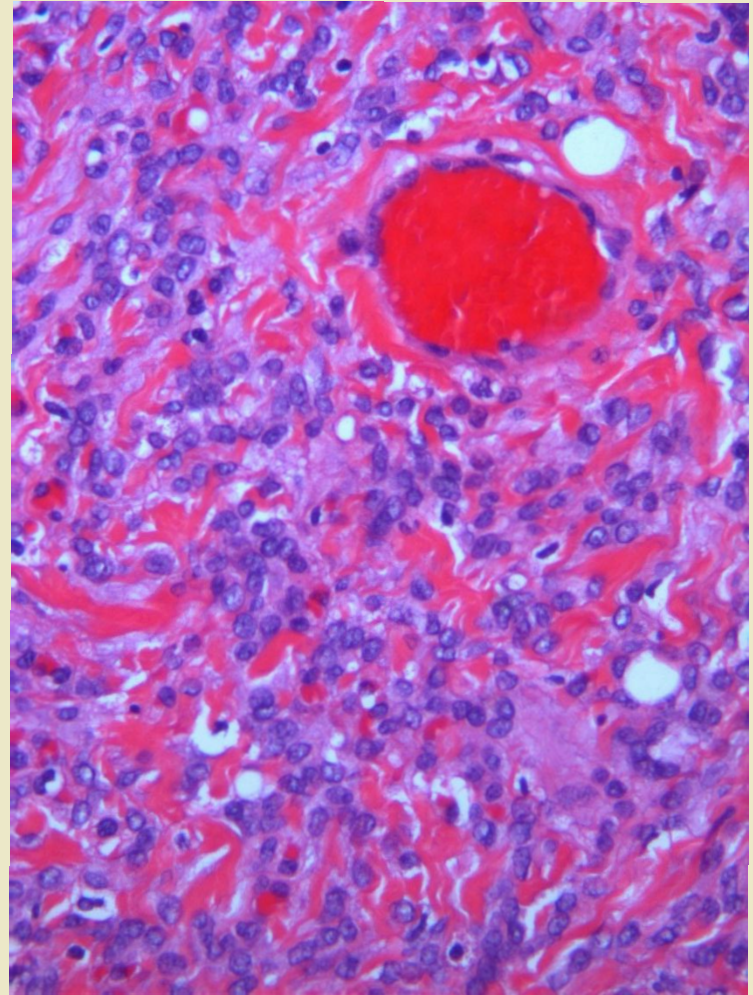
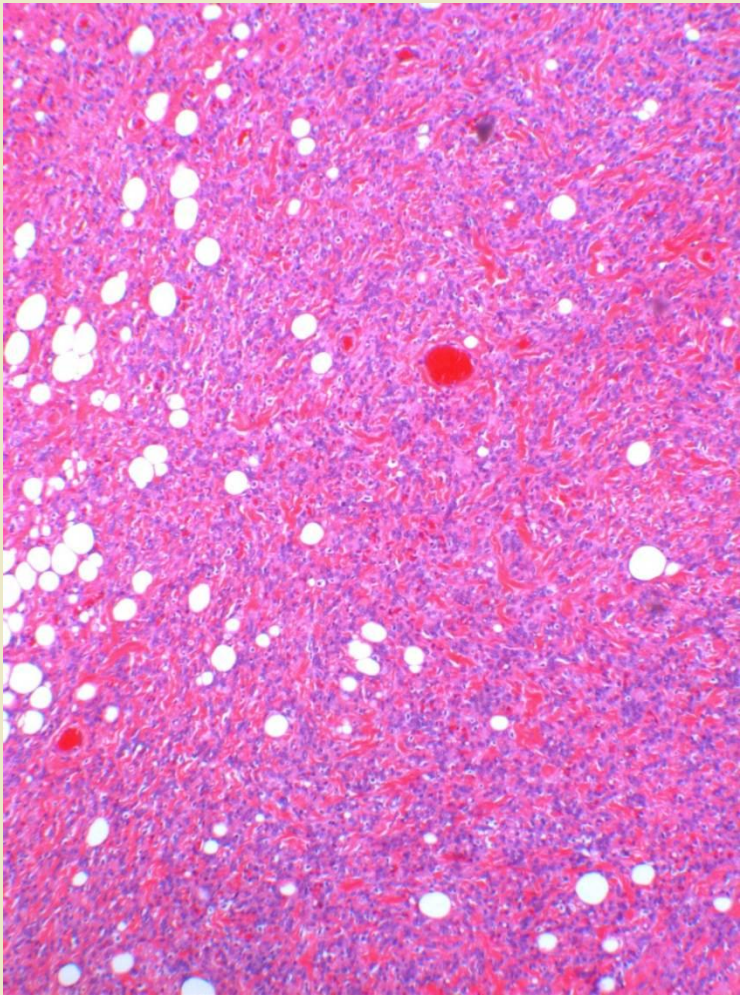
- Liposarcome du cordon

Tumeurs mésentymateuses du cordon spermatique et des annexes testiculaires

Lipome

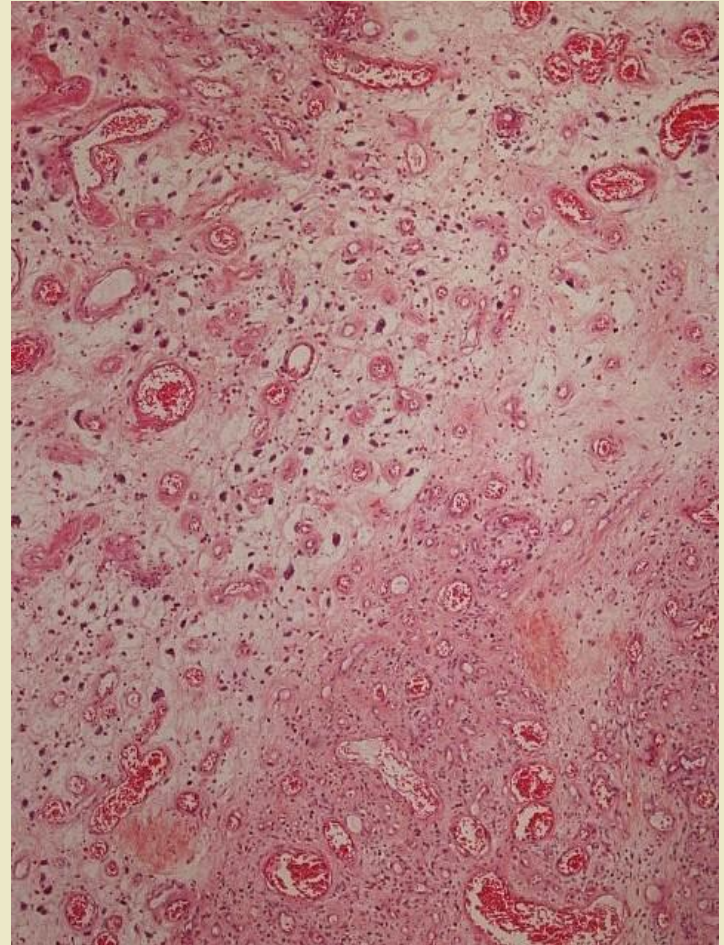
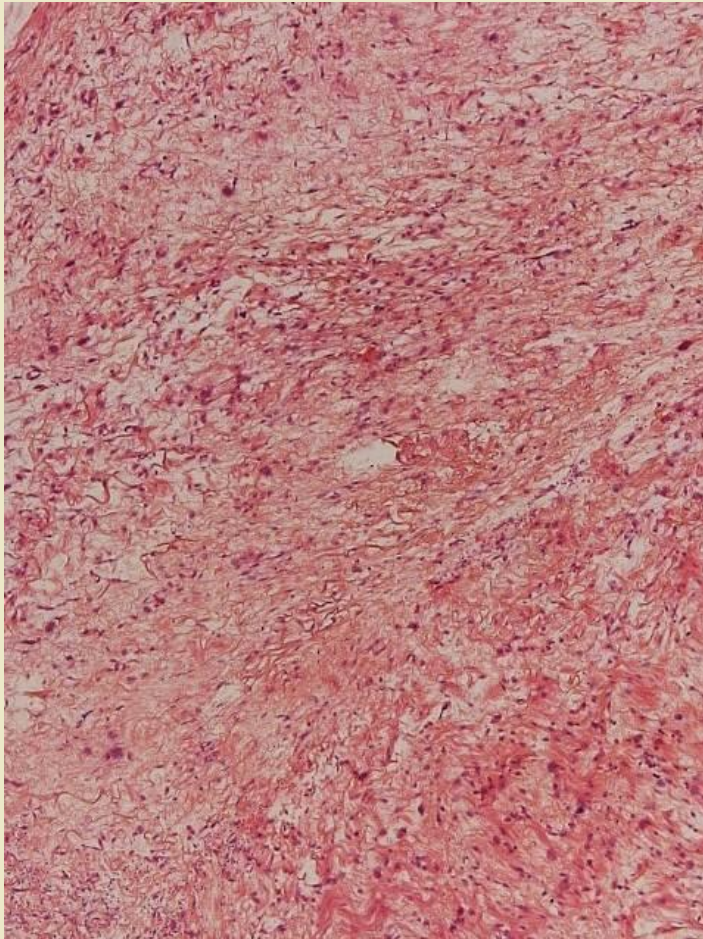


Angiomyofibroblastoma



Liposarcome

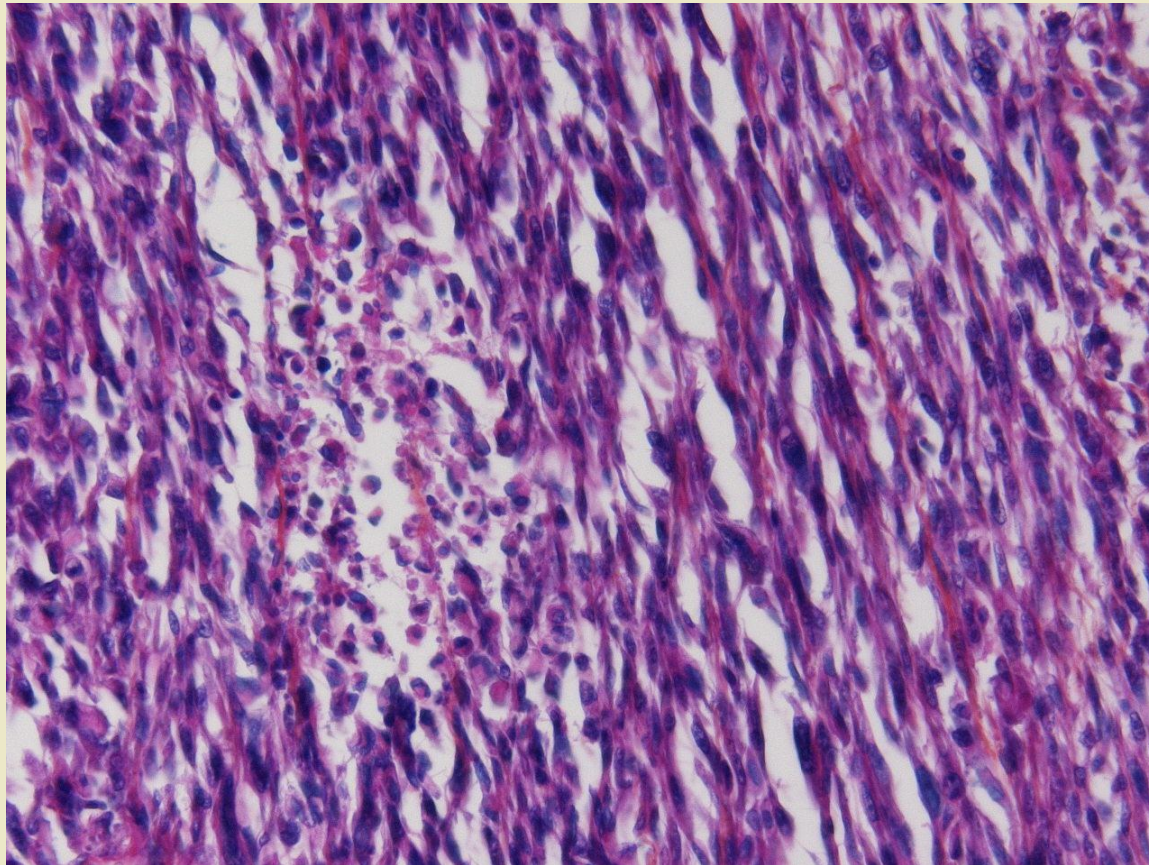
50-80 ans, tumeurs agressives

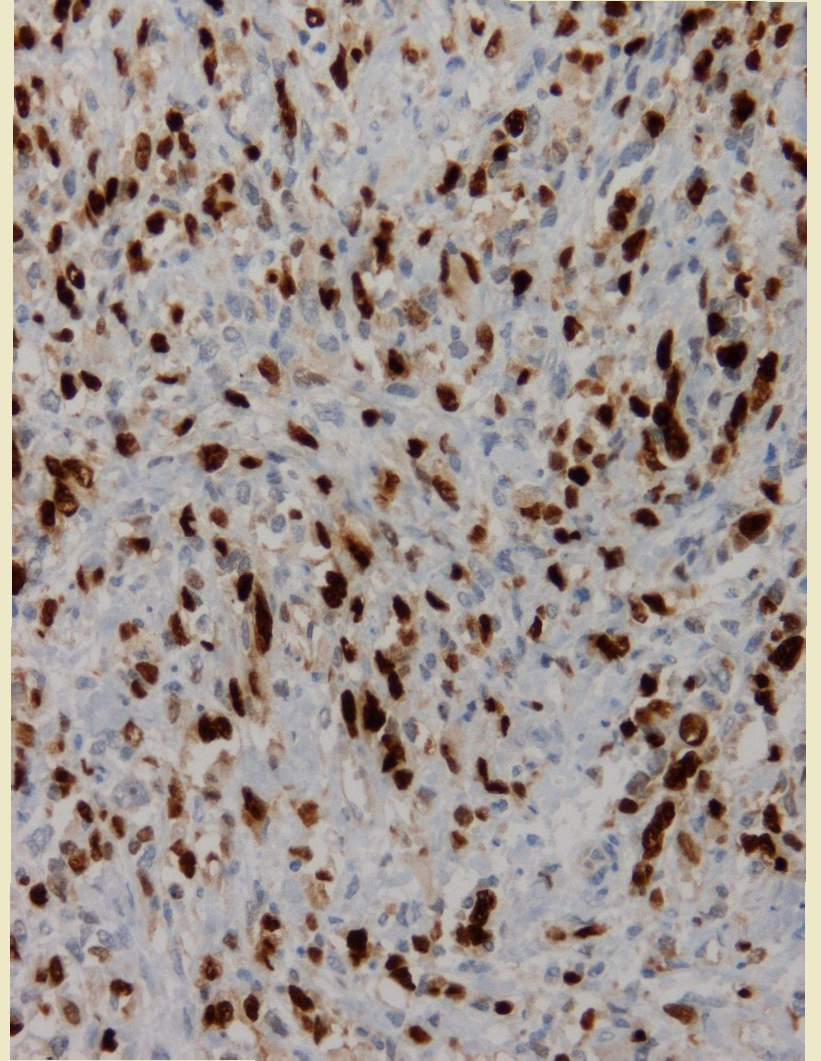
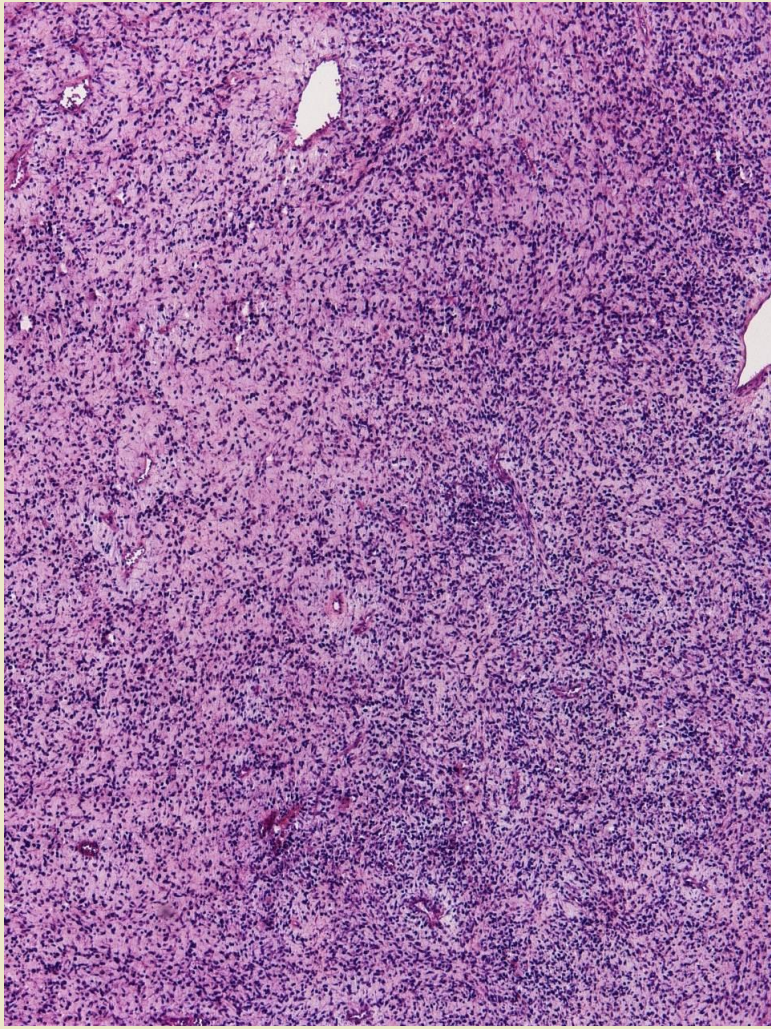


Rhabdomyosarcome

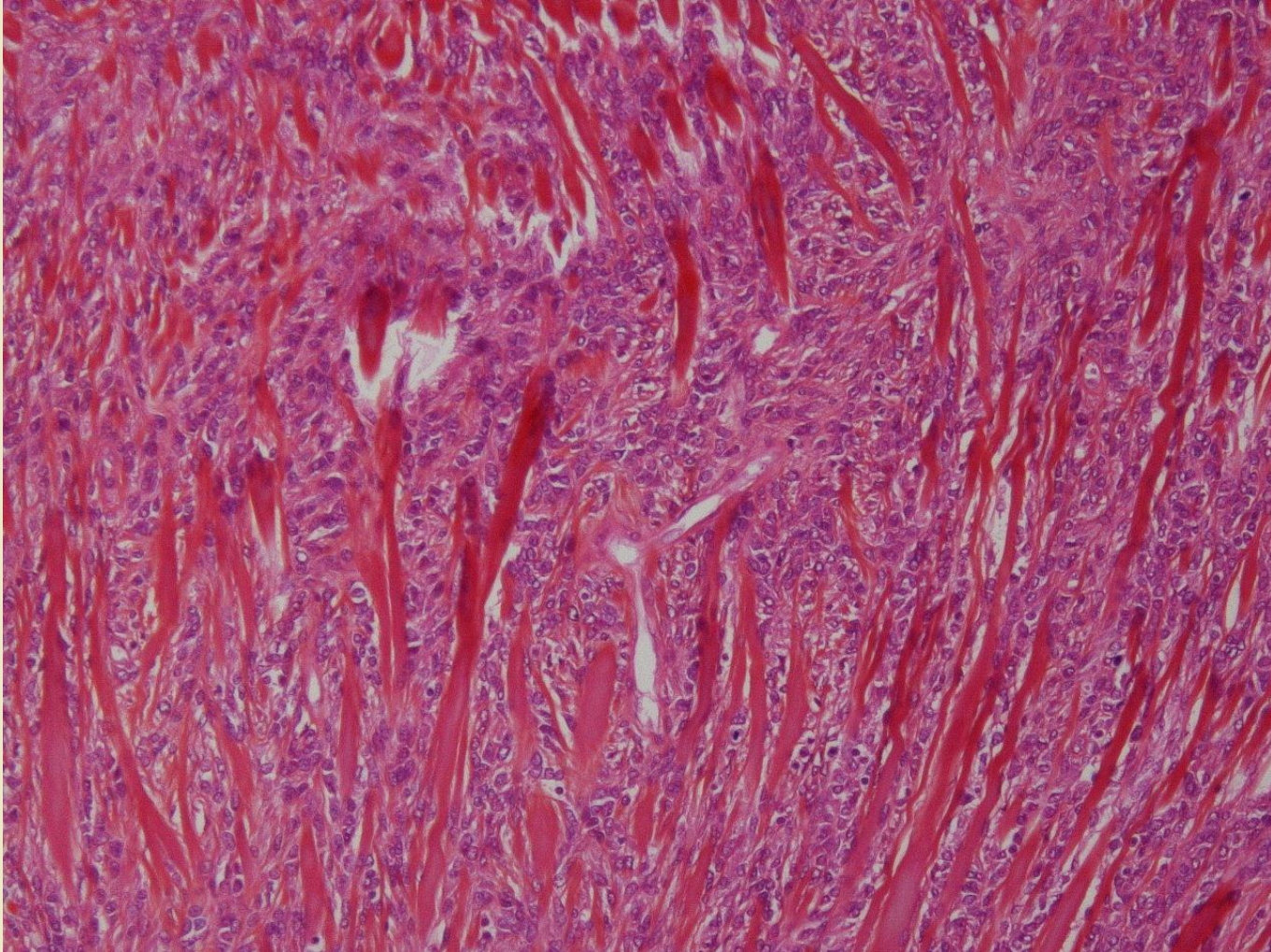
Enfant Adulte jeune < 30 a

Bon pronostic si localisée
(95% survie à 5 ans)





Synovialosarcome



Tumeur desmoplastique à petites cellules rondes

5-40 ans

Extension paratesticulaire d'une
tumeur abdominale ou pelvienne

T(11;22) +++ impliquant EWS et WT1

Très mauvais pronostic