Cas n°4

Histoire clinique :

Femme de 76 ans

Découverte d'une masse surrénalienne avec épanchement pleural gauche

Elévation métanéphrines urinaires 7 µmol / 24 h
et normétanéphrines urinaires 7,5 µmol / 24 h

Chromogranine A : 103 ng/ml

TDM :

lésion surrénalienne gauche nodulaire 30 mm diamètre washout de 28 %

rehaussement tardif d'une plage hypodense centrale

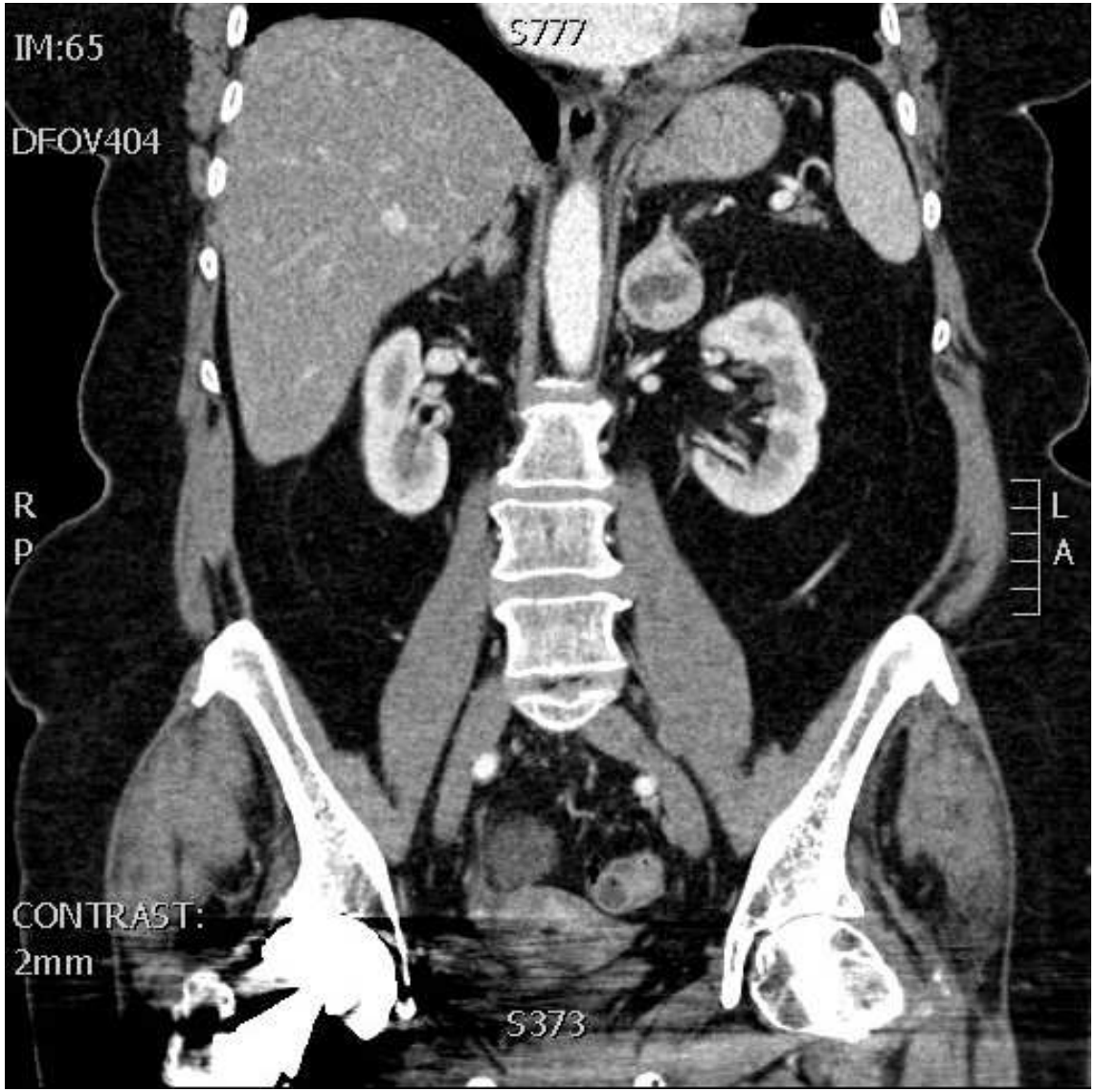

→ Surrénalectomie gauche

Macroscopie :

- Surrénalectomie gauche
- 31g, 9 x 4 x 2 cm

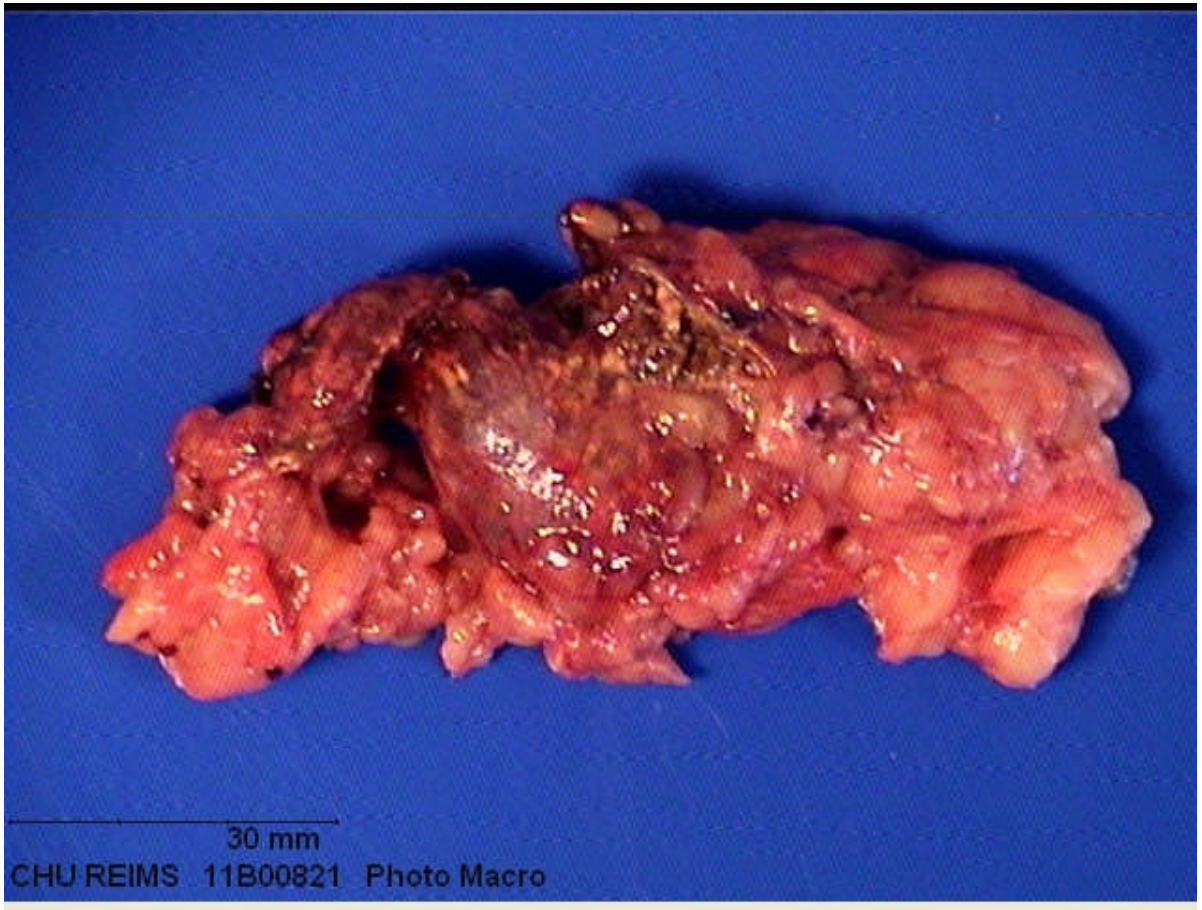

Macroscopie :

- Tumeur beige kystisée de 25 mm de ∅

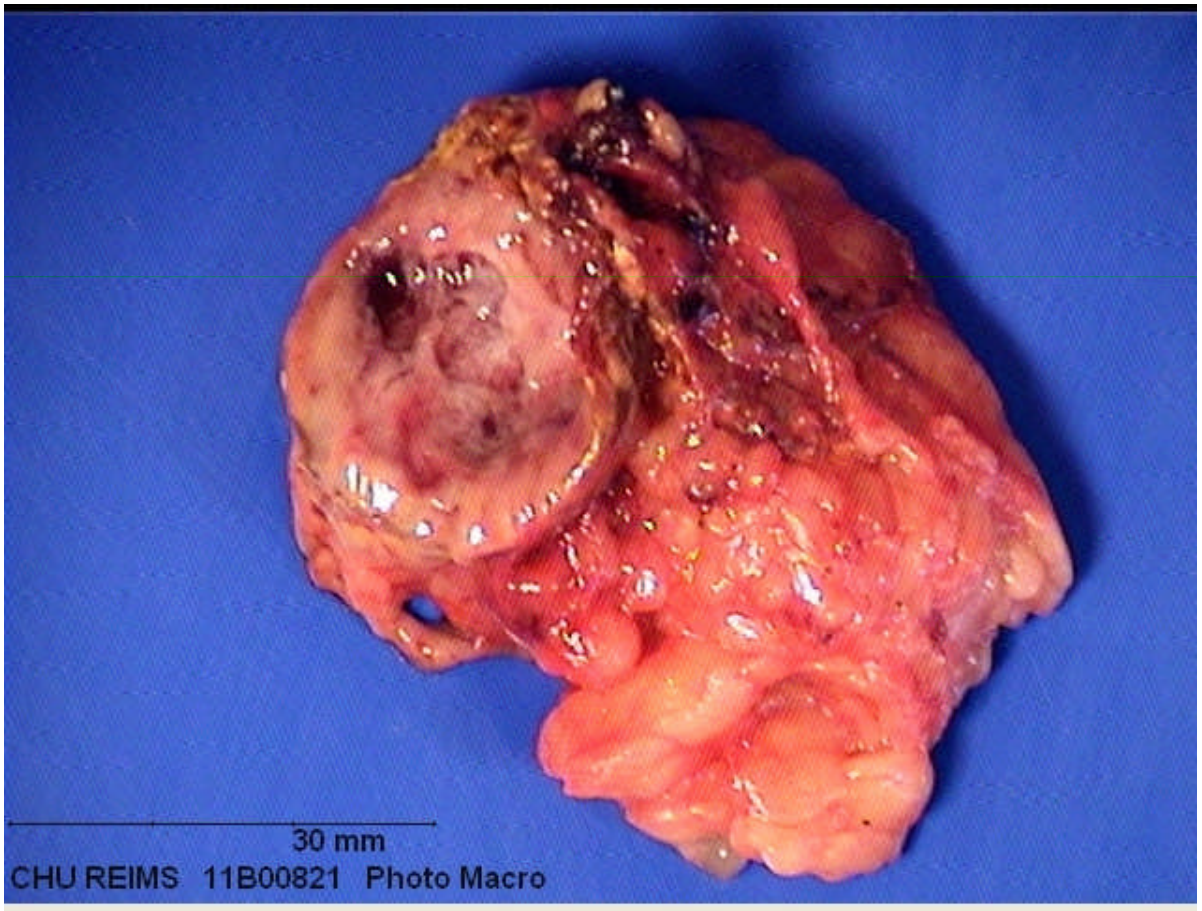

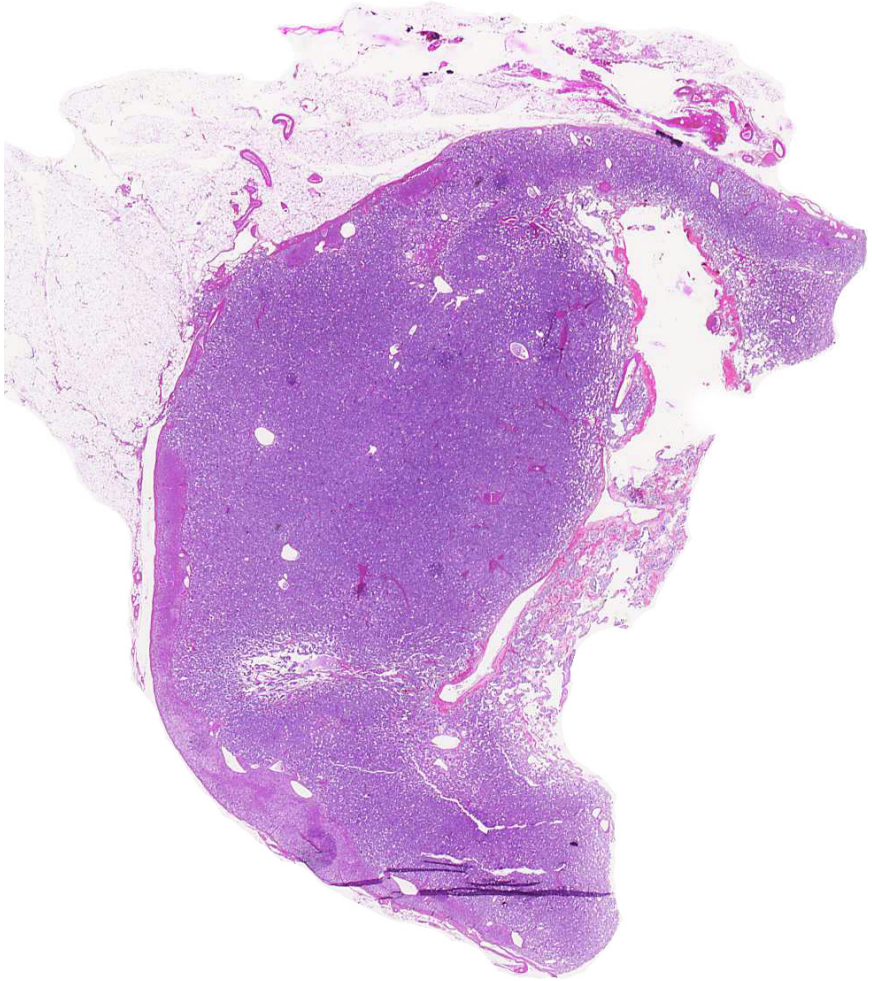

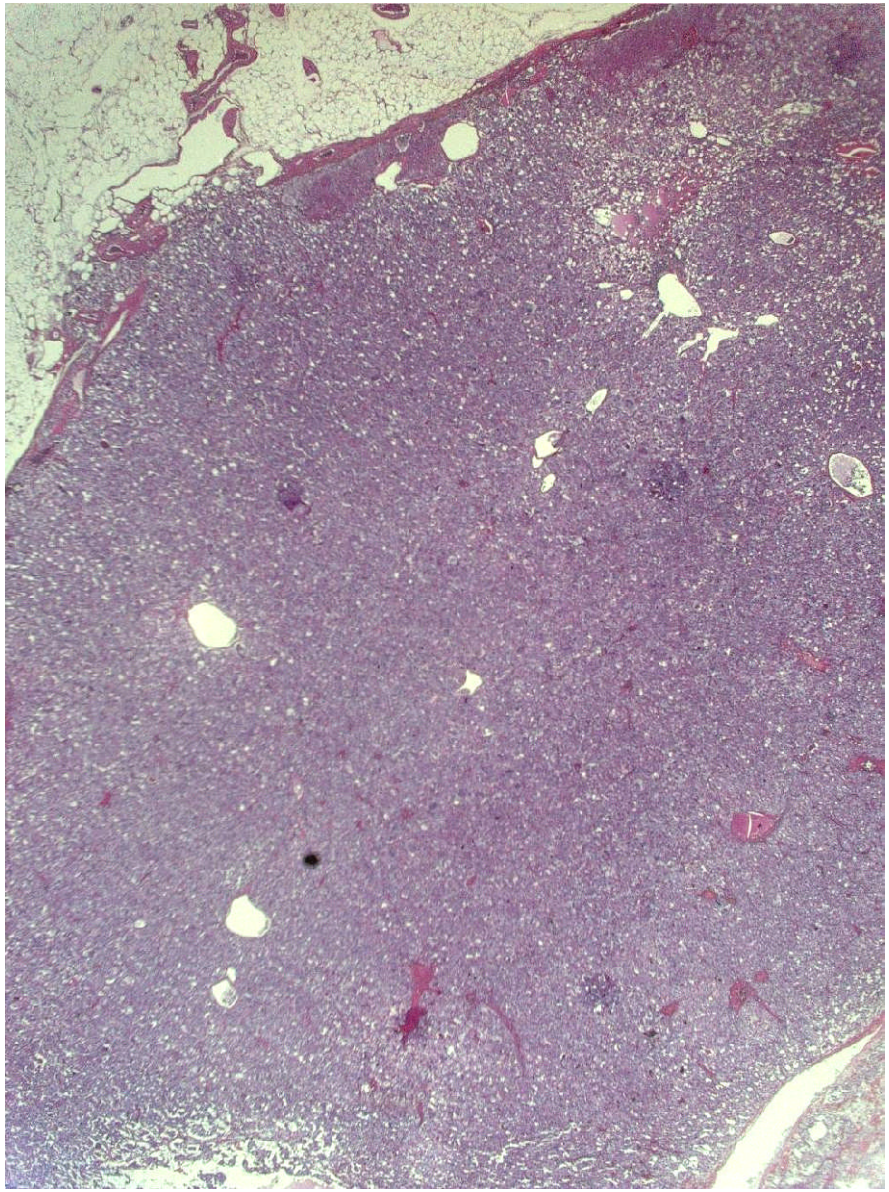

Jonction cortex phéo

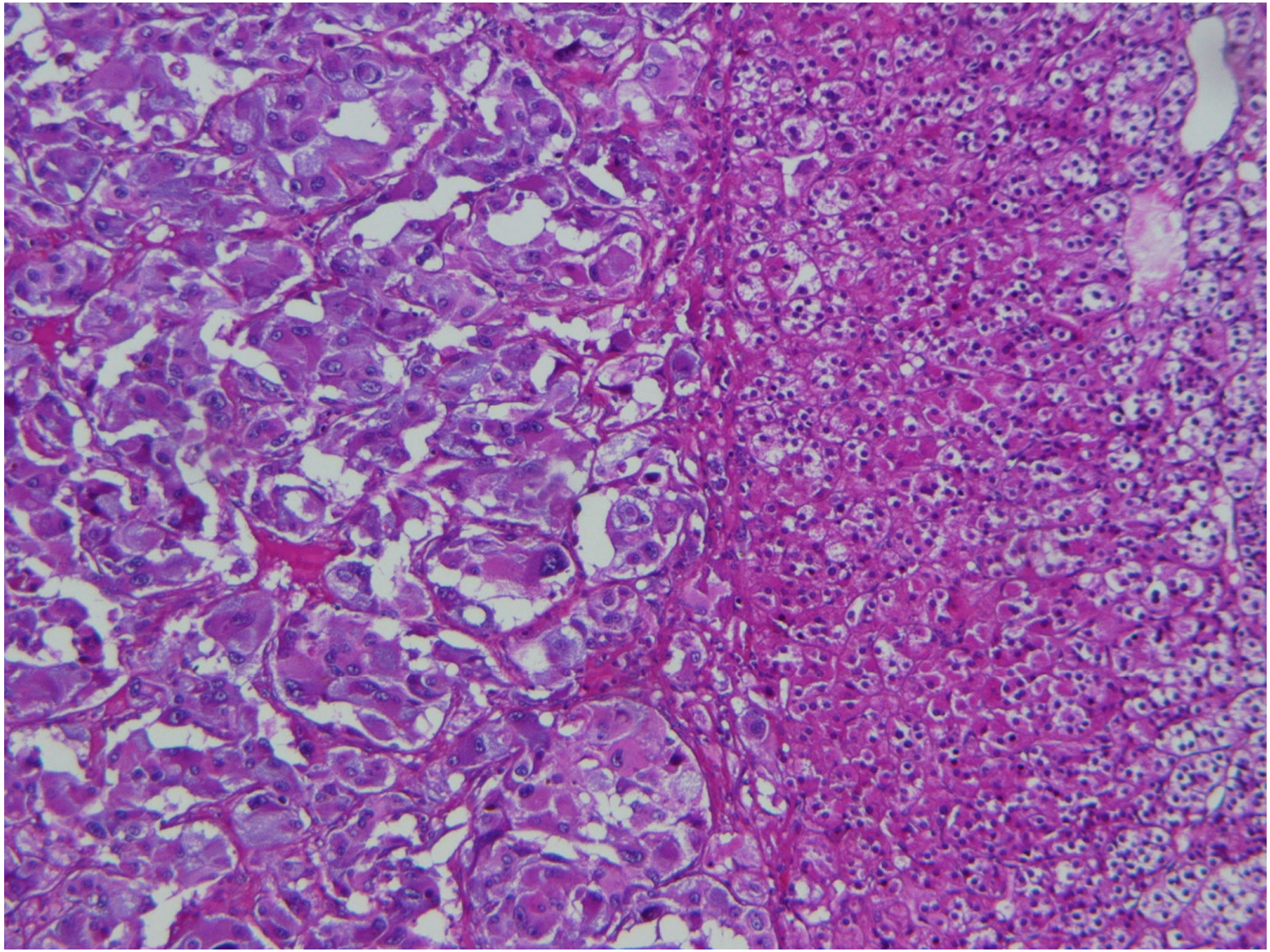

NB cortex infiltrant le tissu cellulo-adipeux périsurrénalien

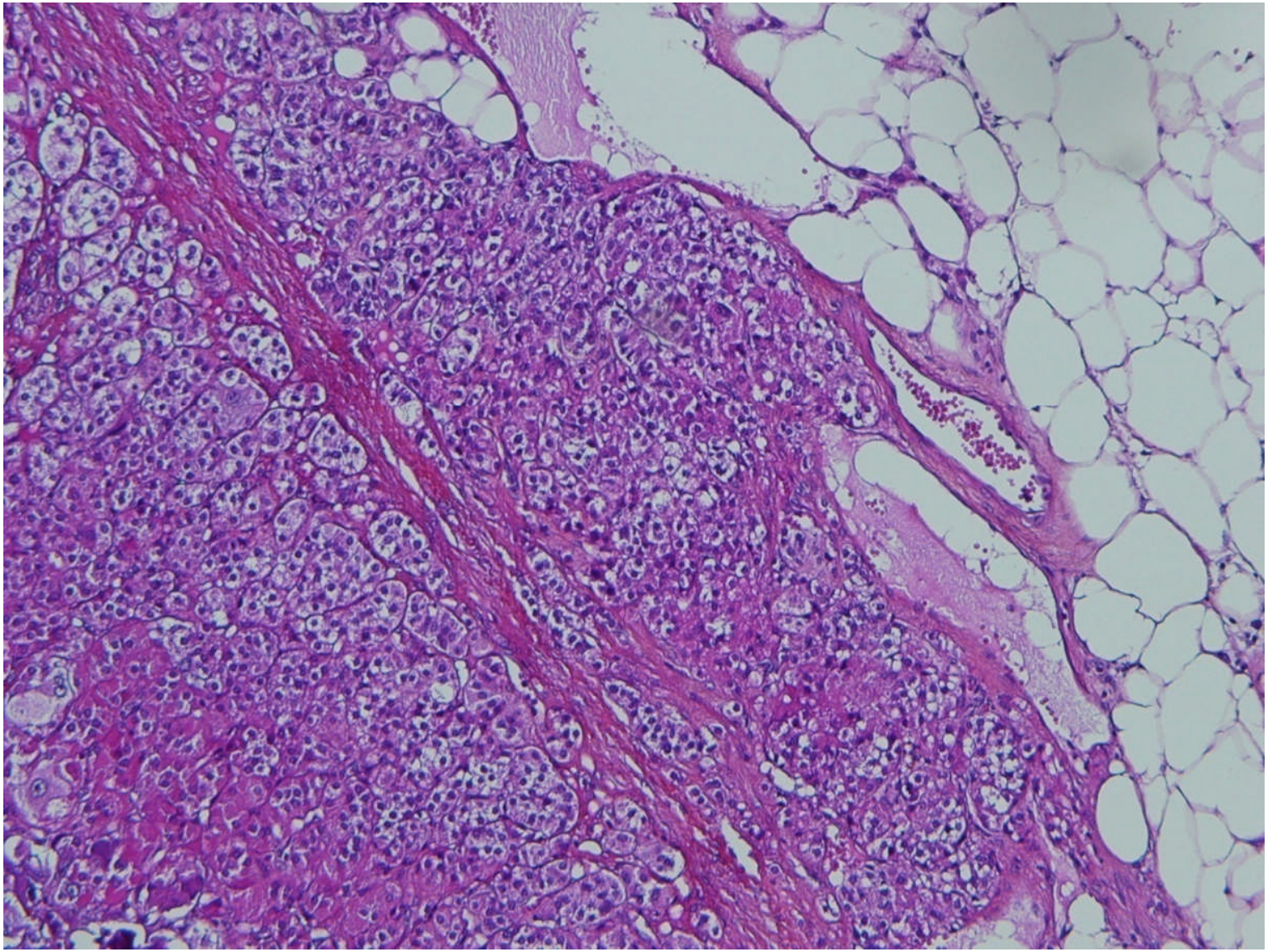

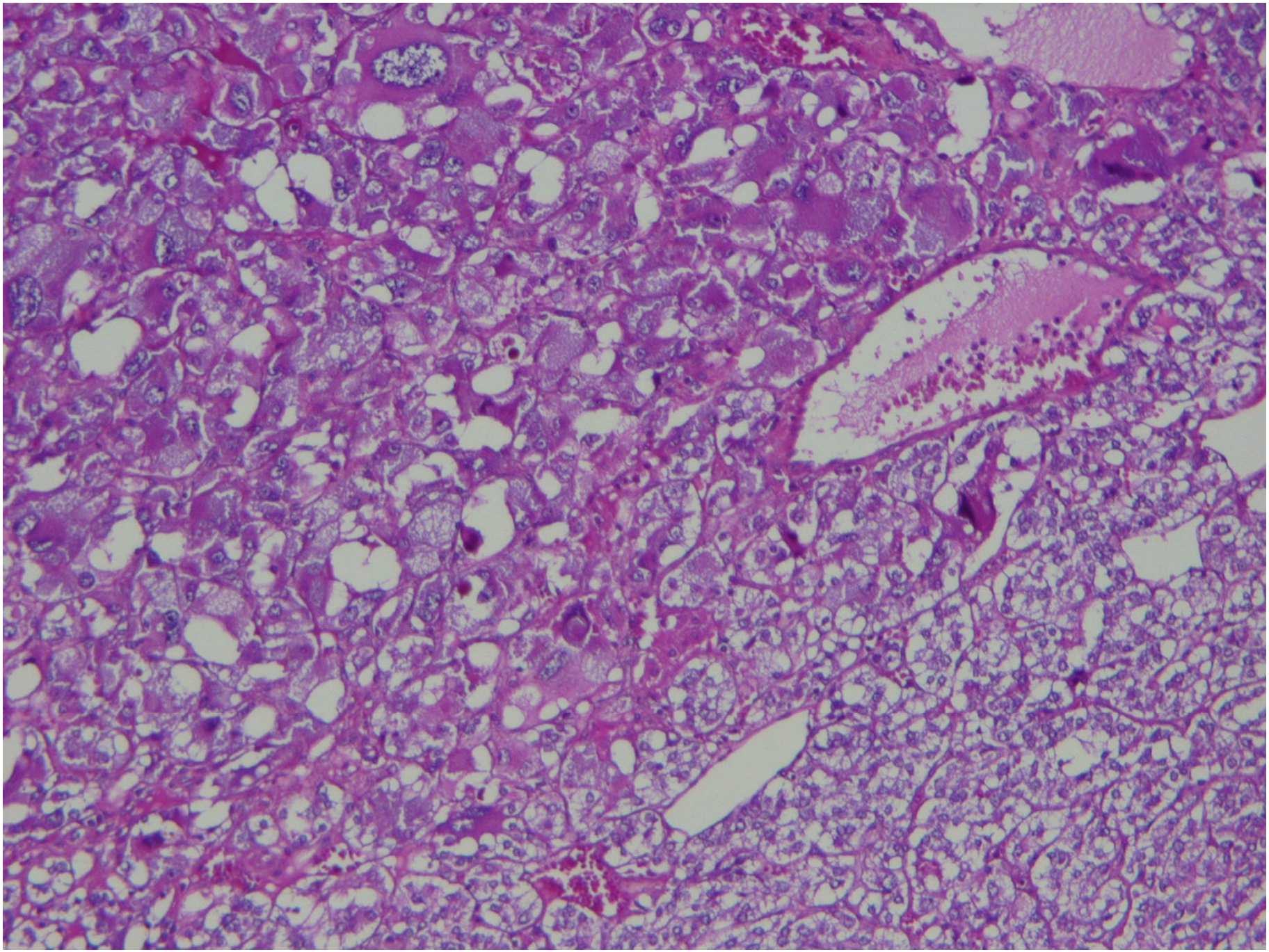

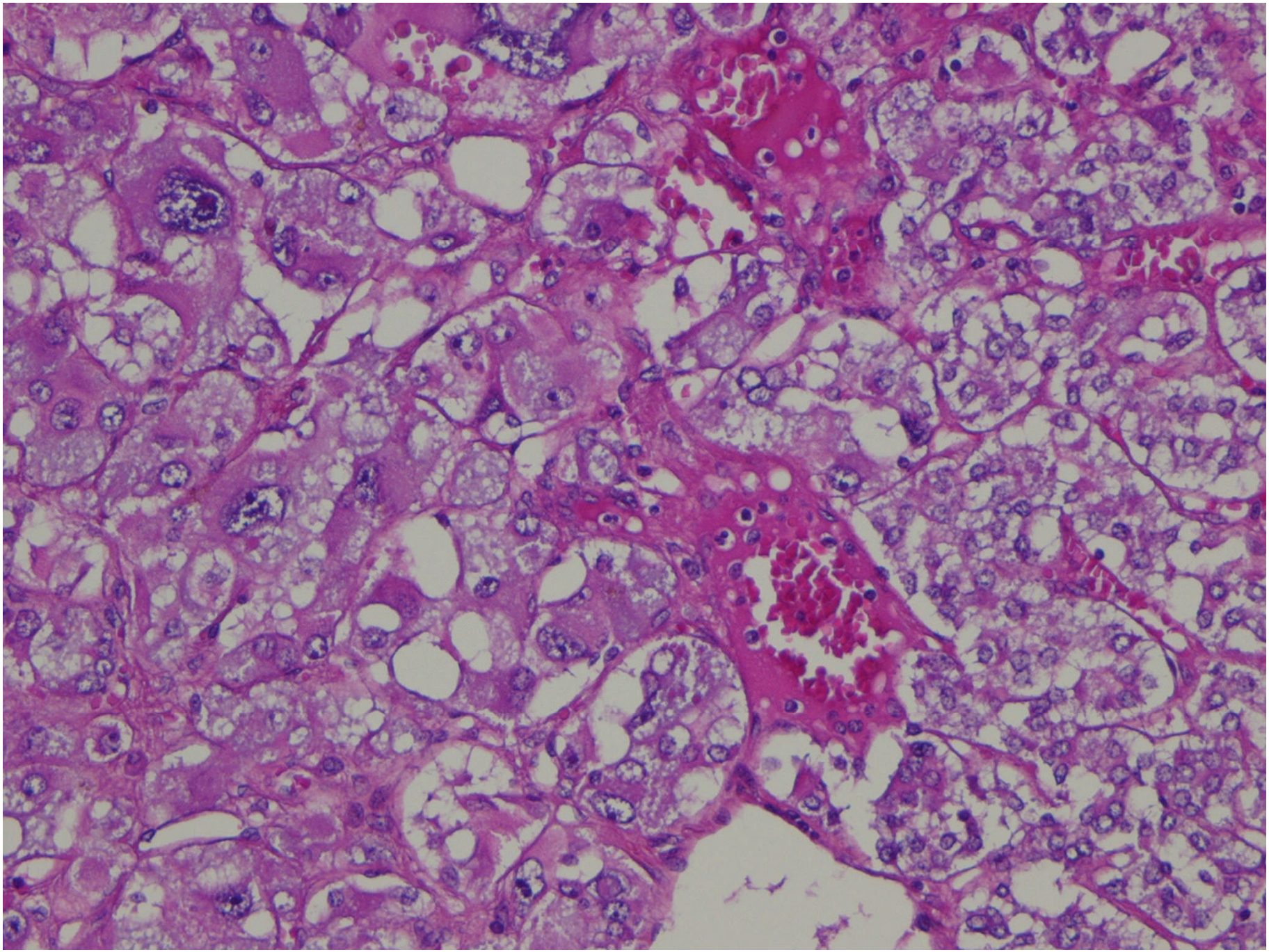

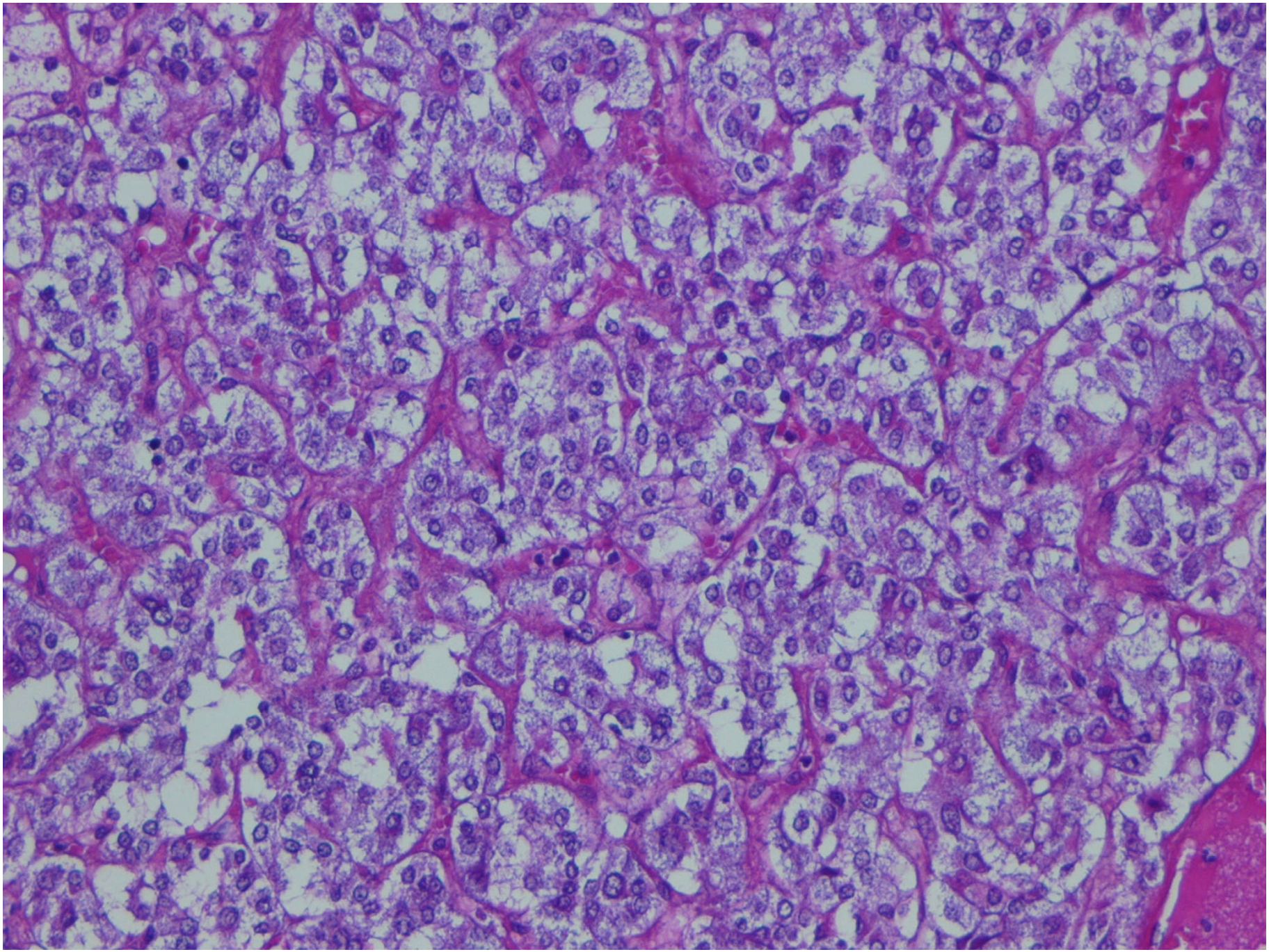

Architecture en nids « zellbalen »
Cellules à cytoplasme granuleux

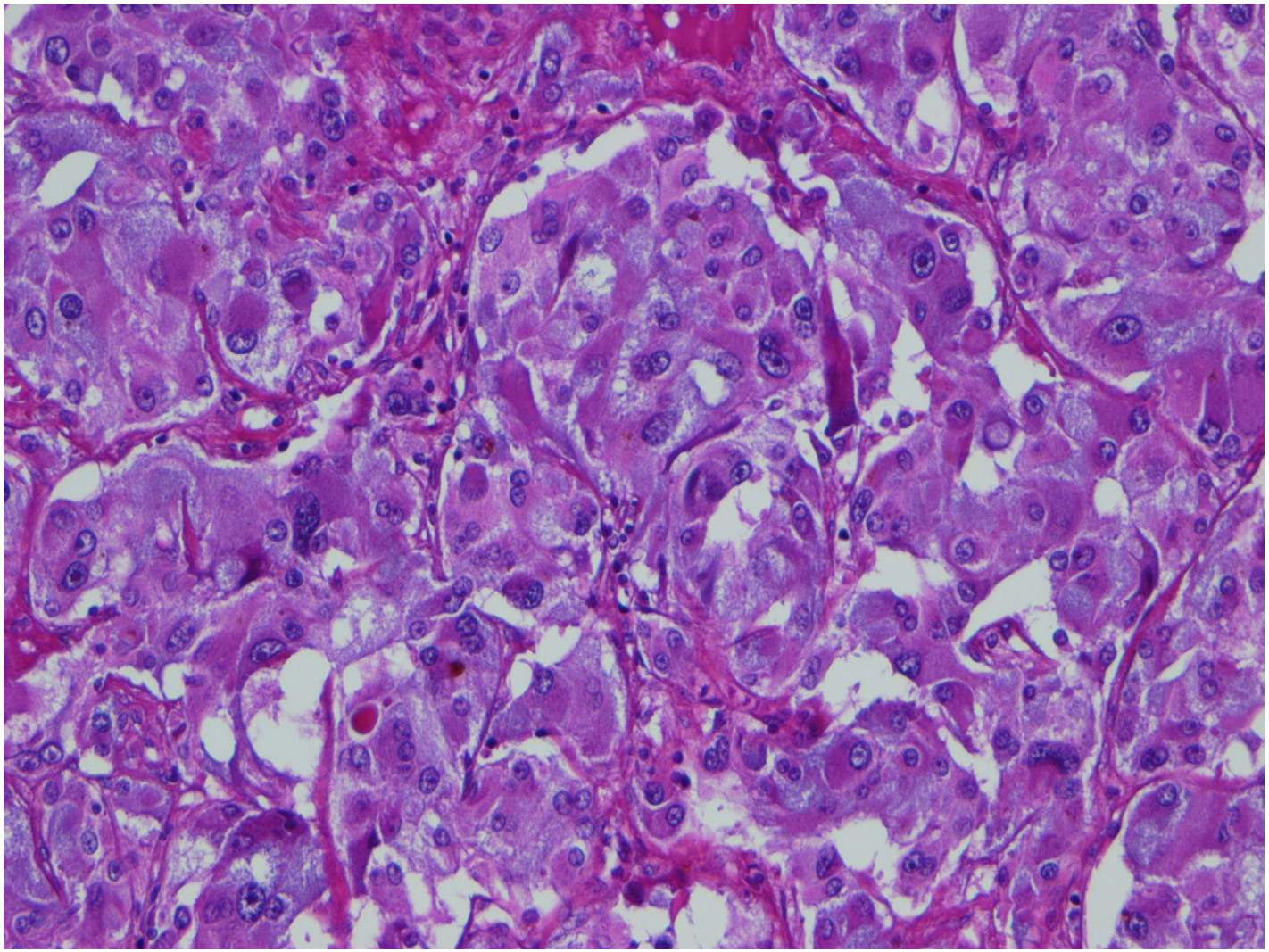

Remaniement kystique central

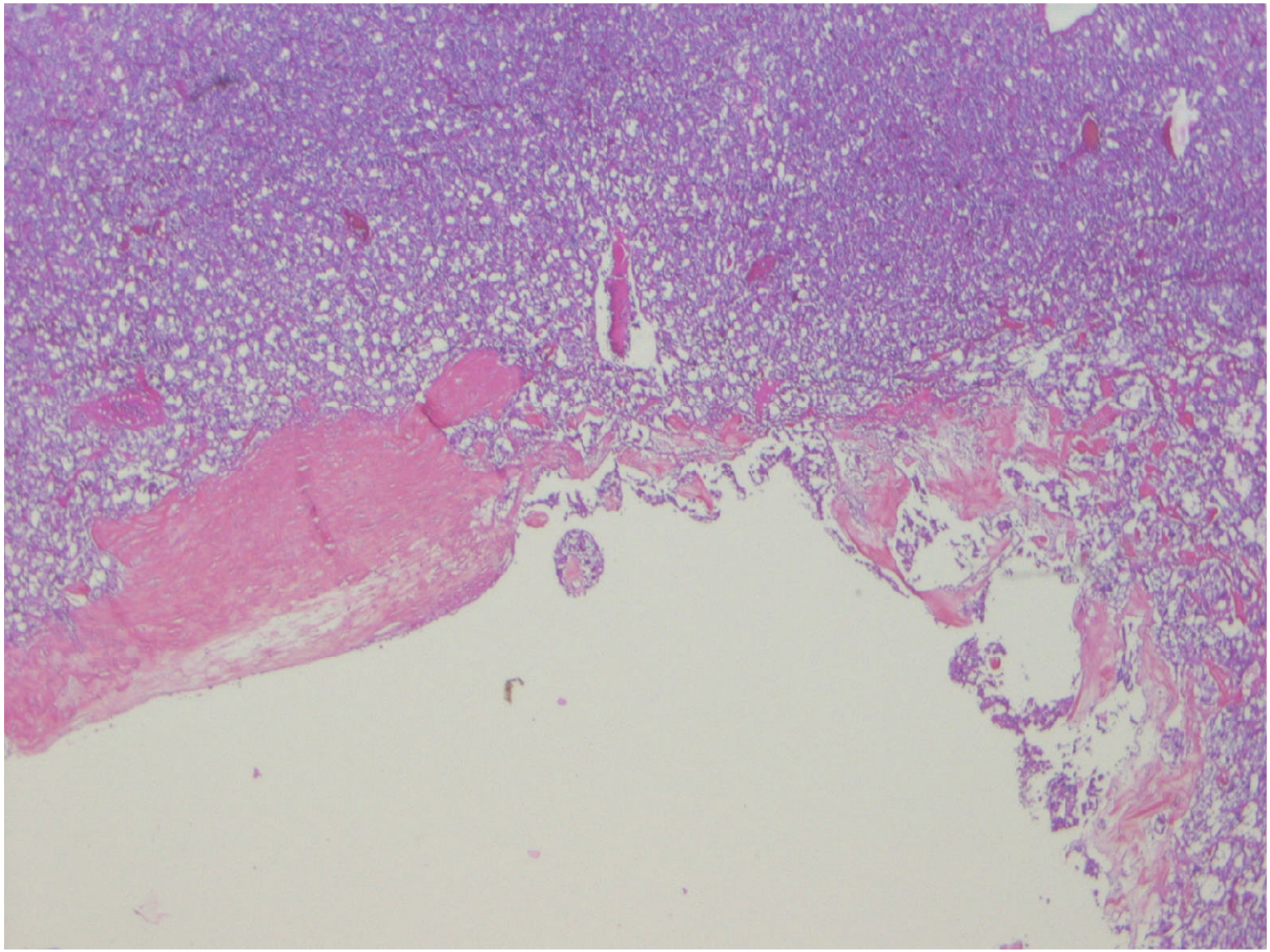

Cellules à noyau arrondi à chromatine fine peu nucléolée globi hyalin

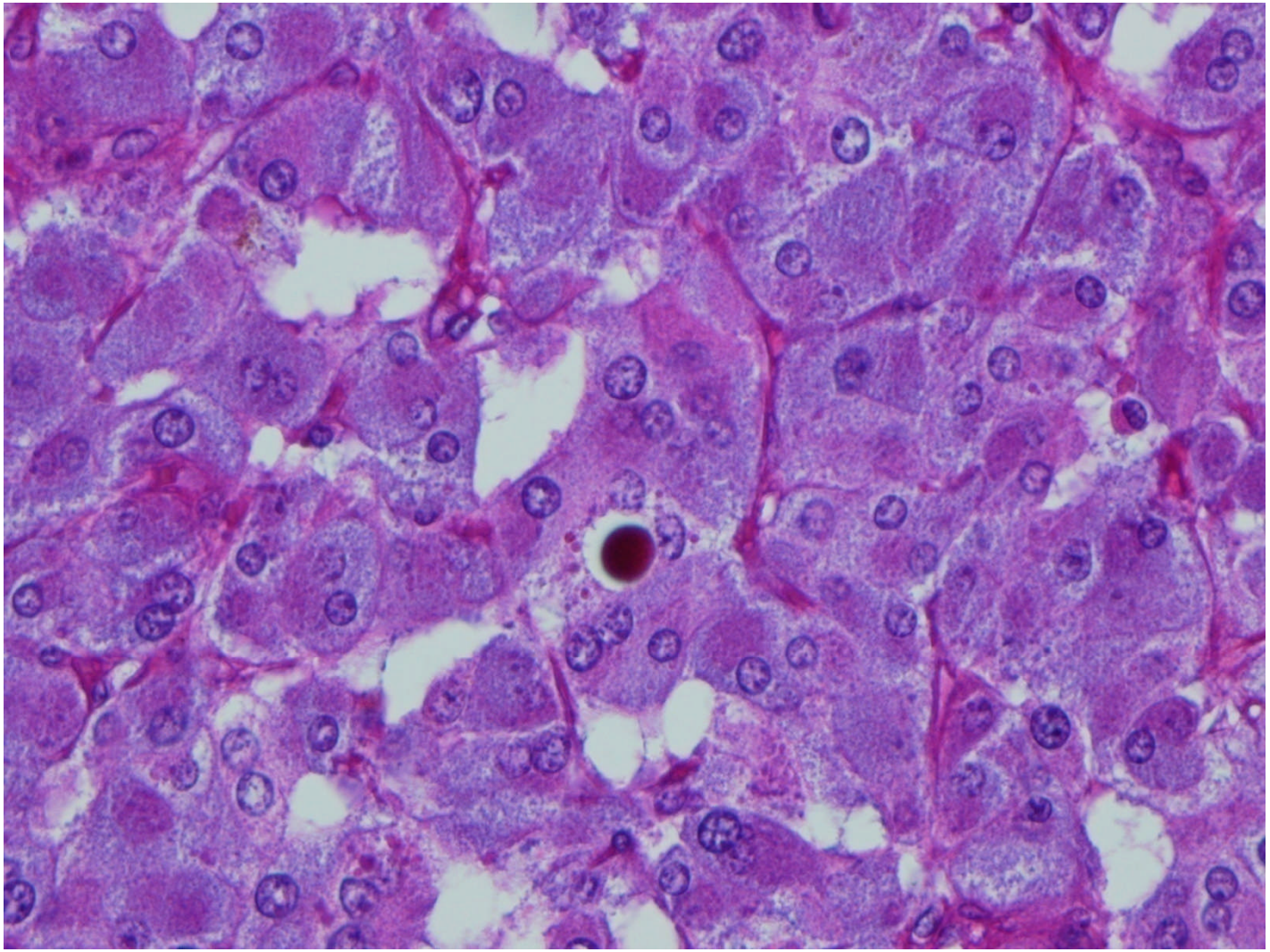

Vacuoles intranuclaires

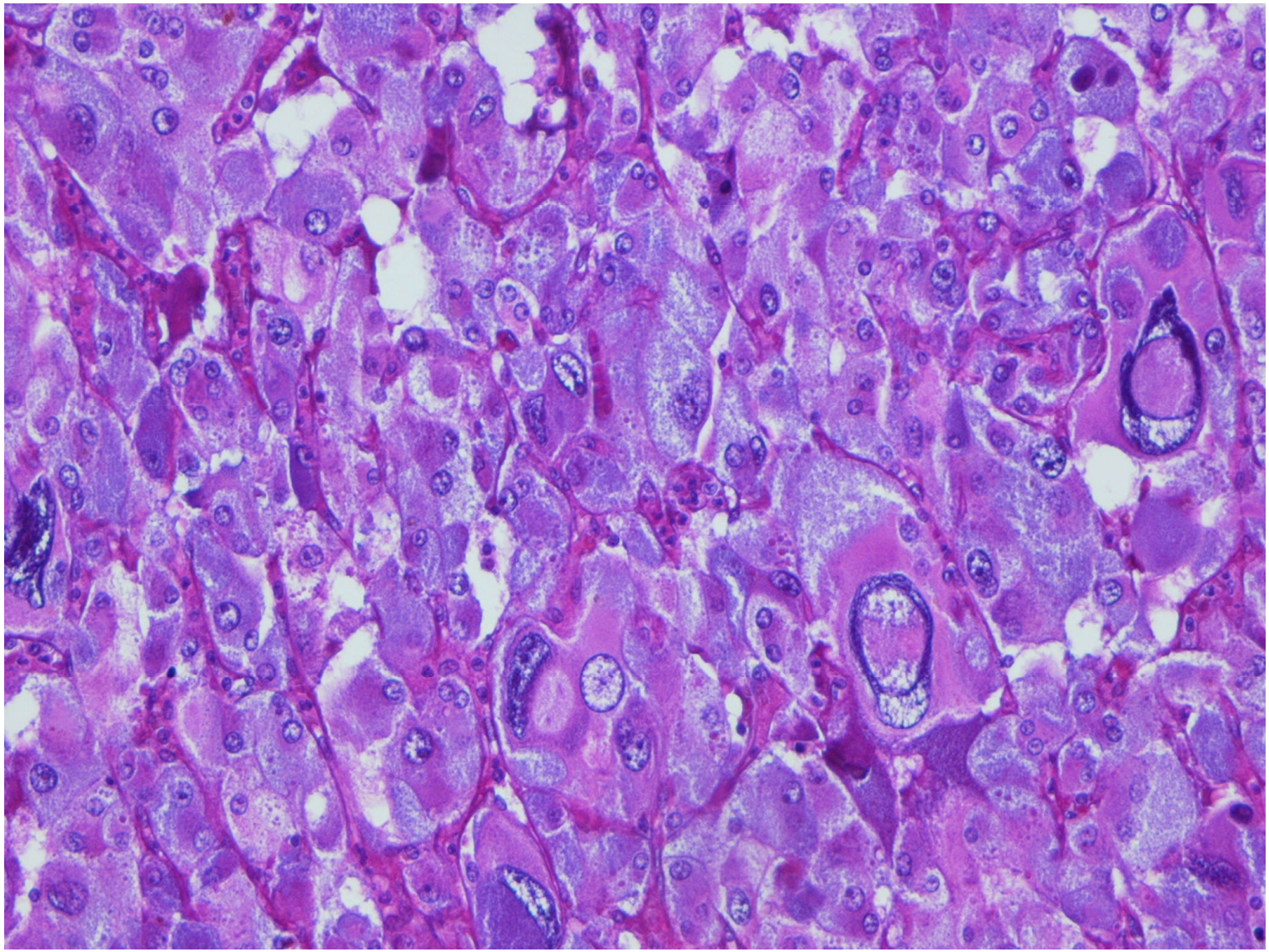

Atypies cytonucléaires
Anisocaryose
Hyperchromatisme noyau irrégulier (côté 1)

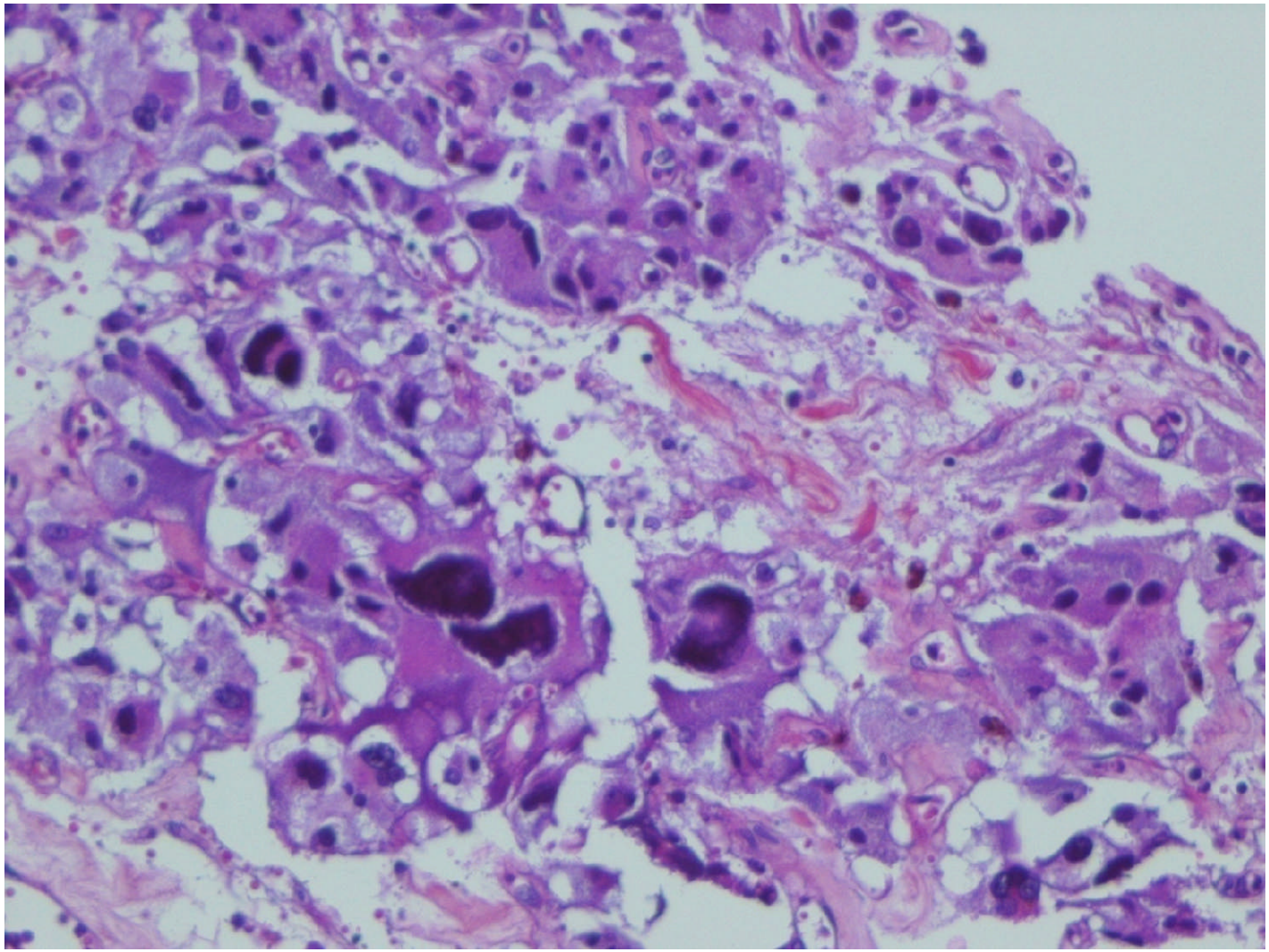

Effraction capsulaire focale et infiltration du tissu cellulo-adipeux périsurrénalien (côté 2)

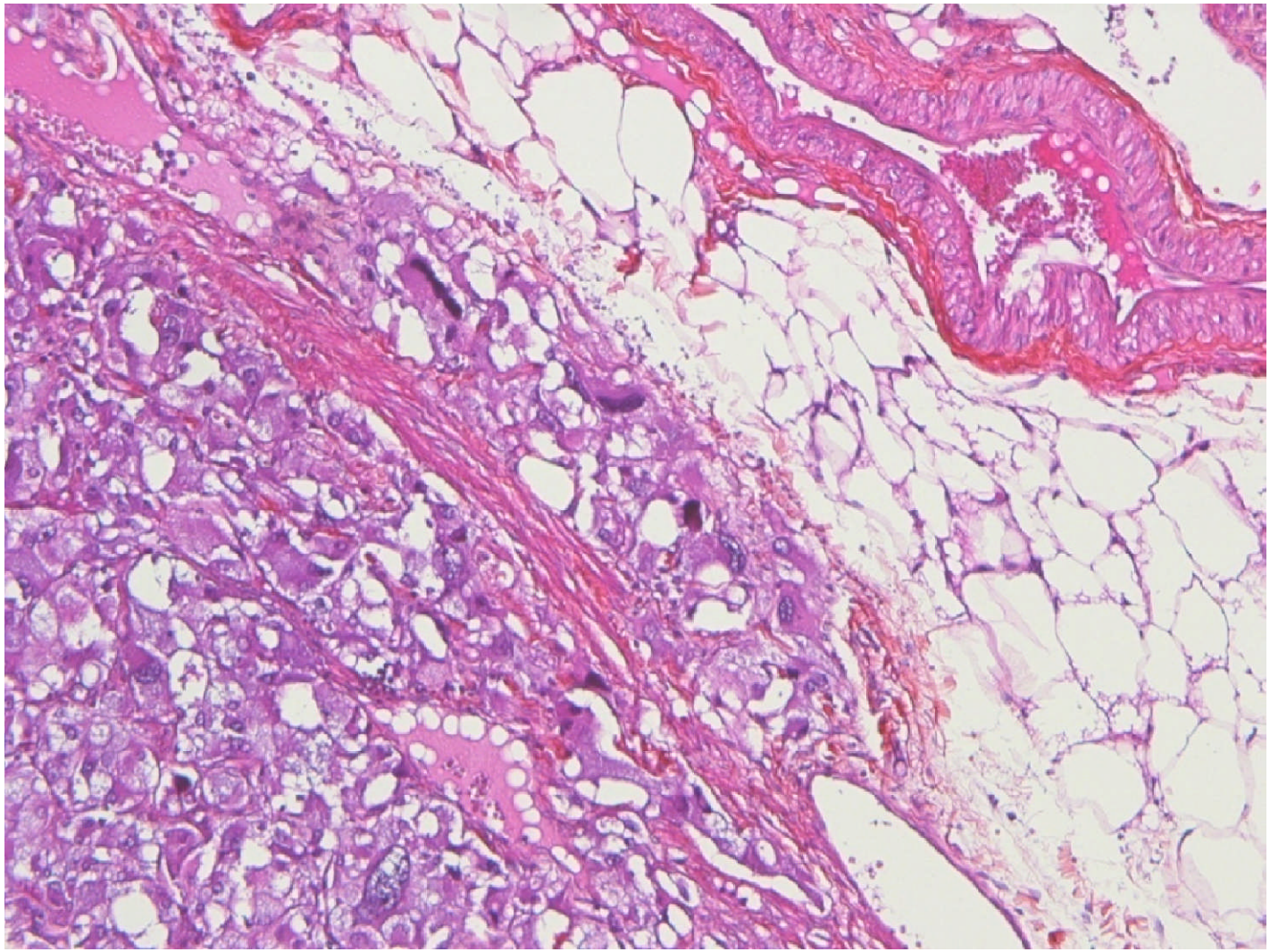

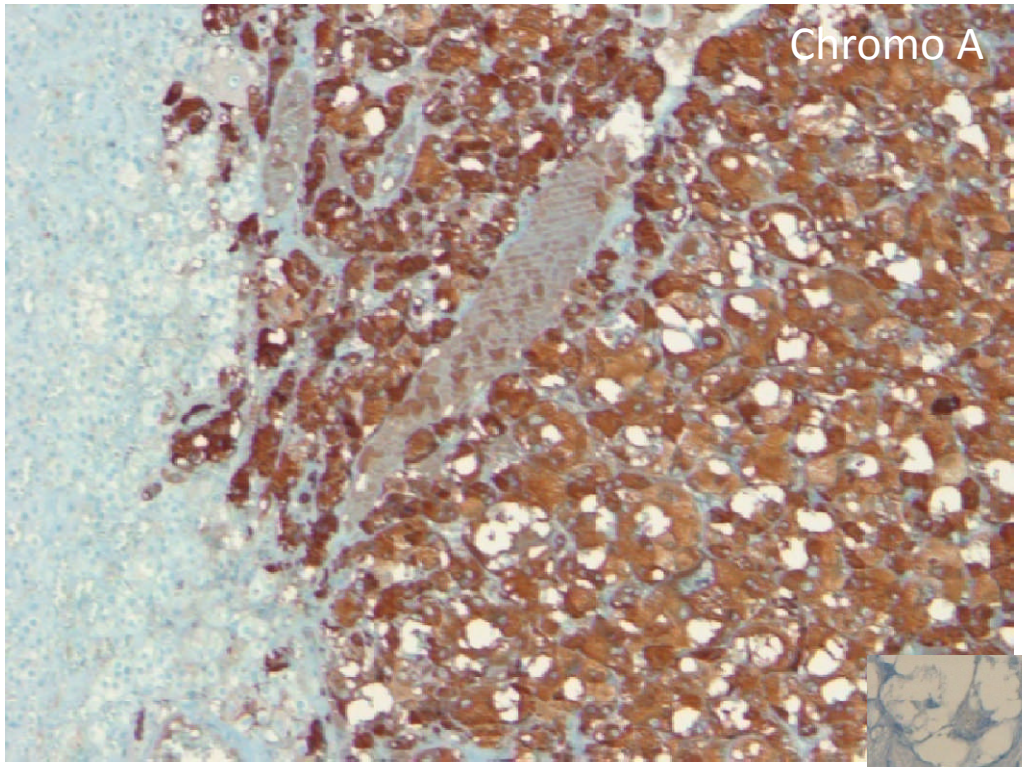
Chromo A

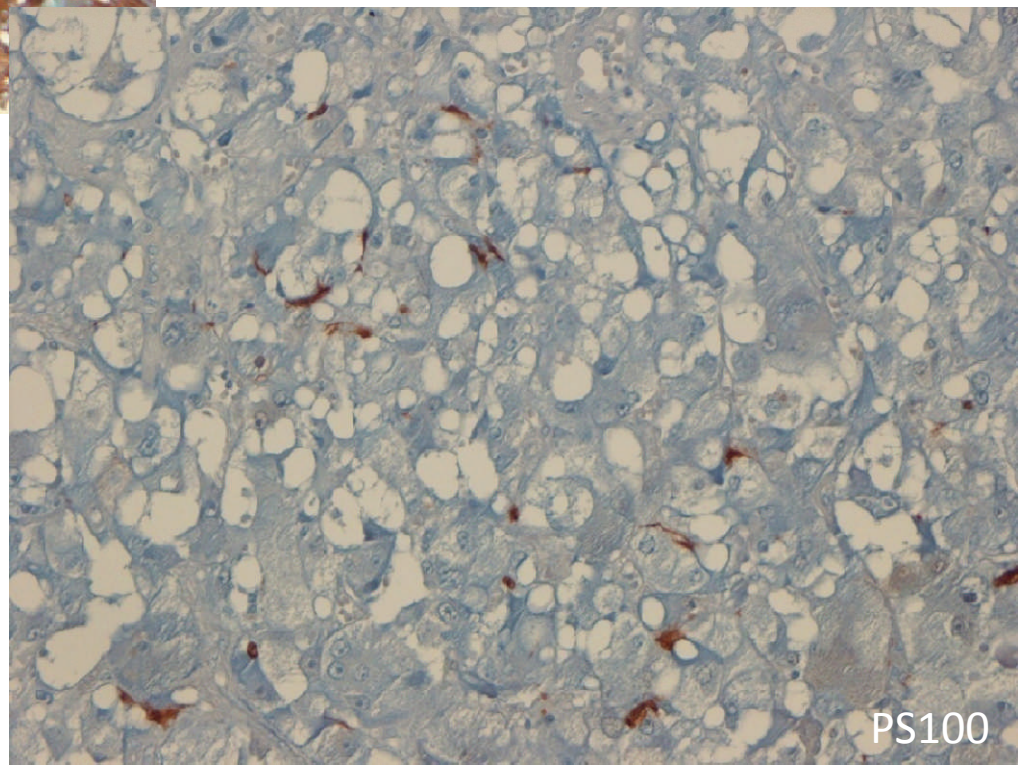
PS100

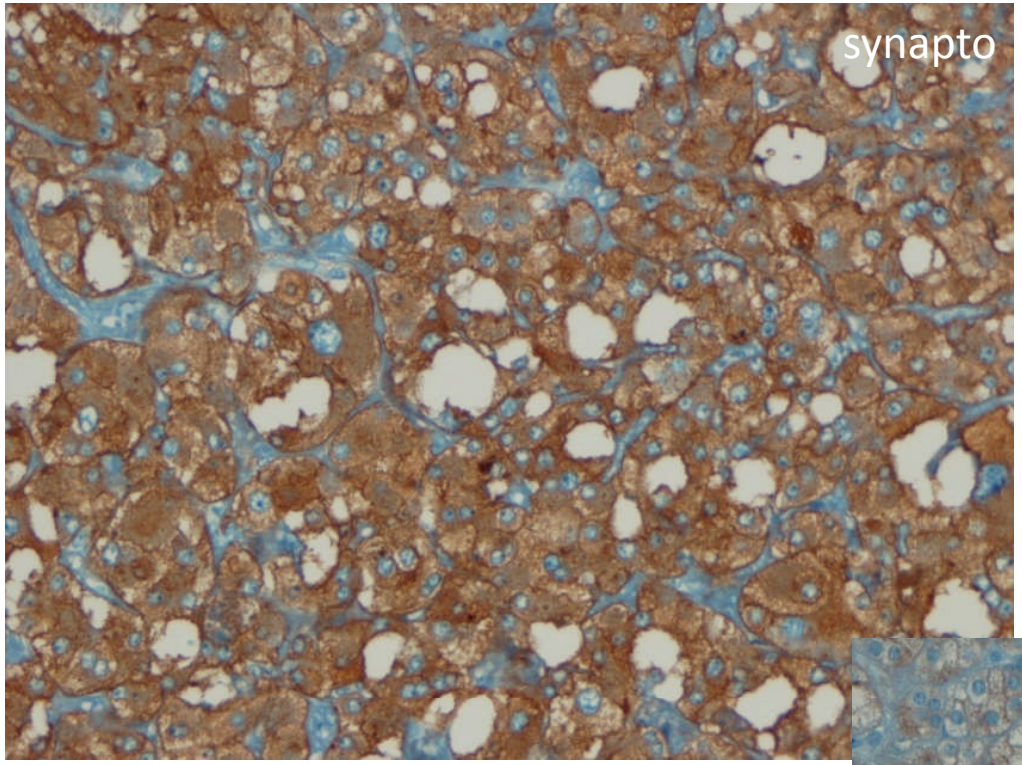
synapto

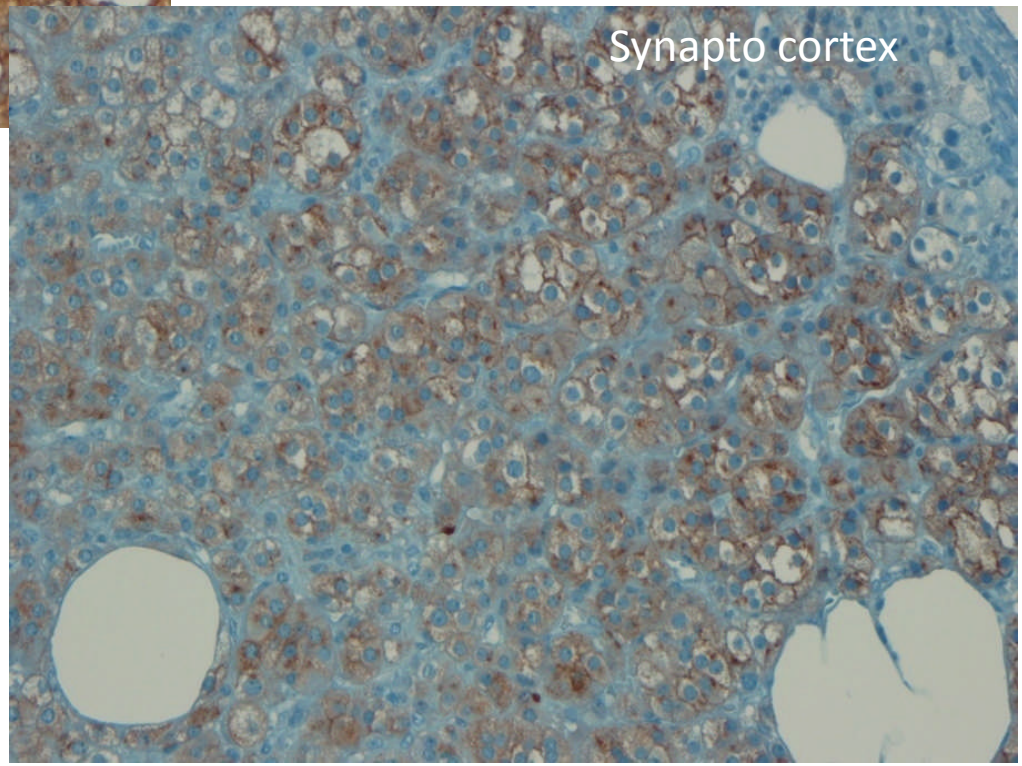
Synapto cortex

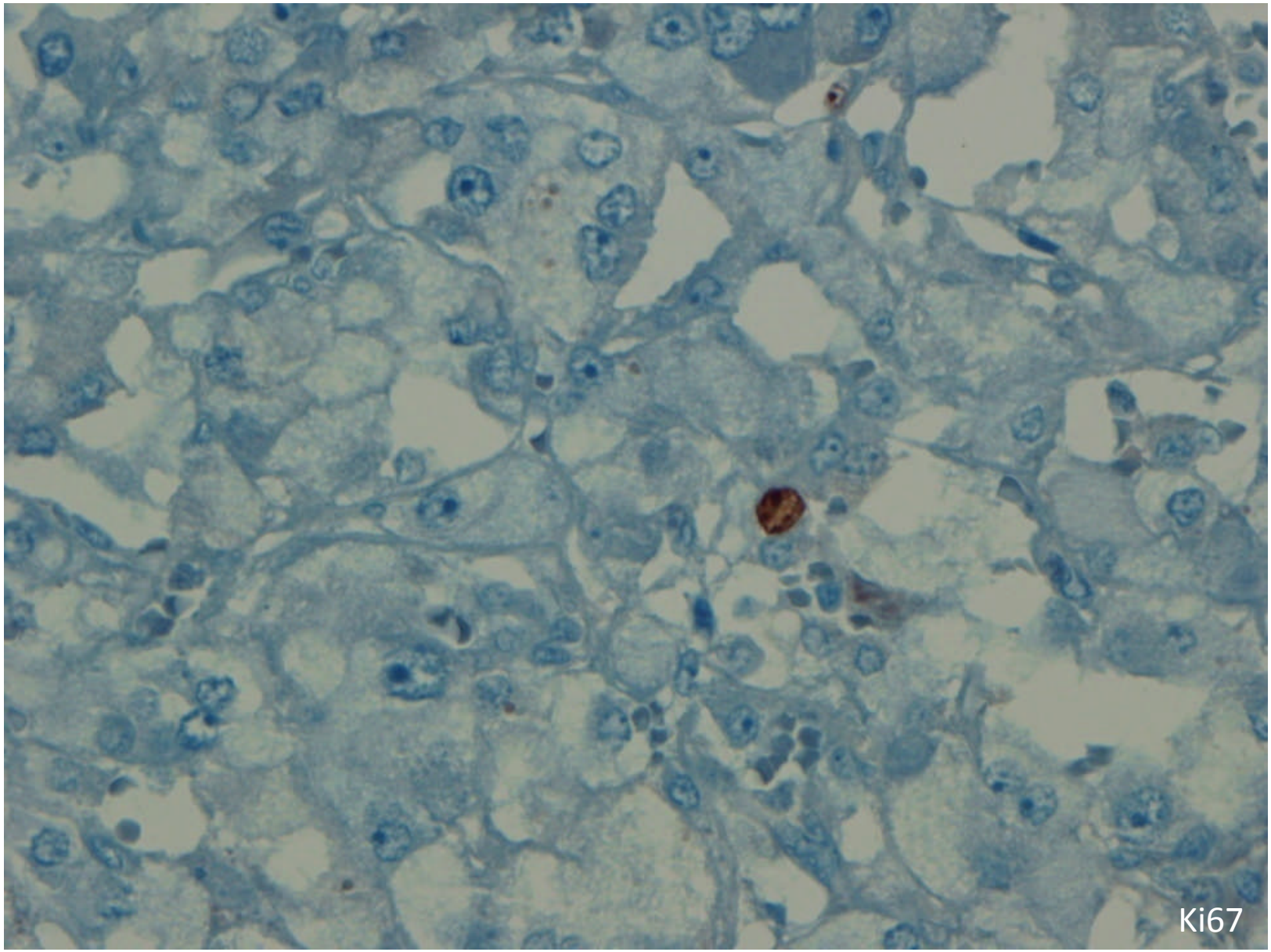
Ki67

Diagnostic proposé

- Phéochromocytome de score PASS 3 ?

Commentaires

- Extension du tissu adipeux x2
- Pleiomorphisme cellulaire nucléaire sévère x1
- → score PASS 3
- Bien que le score Pass ne soit pas validé son utilisation permet une évaluation des critères d'agressivité et fournit une liste d'items à évaluer dans le phéochromocytome ainsi les éléments devant figurer dans le compte rendu

Bibliographie :

- Patey M. Pheochromocytoma and the diagnosis of malignancy : recent date and the role of the pathologist. Ann Pathol 2008 Nov ; 28 Spec N°1 (1) : S42-44
- DeLellis RA, Lloyd RV, Heitz PV, Eng C. Pathology and Genetics of Tumours of Endocrine Organs. World Health Organization Classification of Tumours. *IARC* Press, Lyon, 2004
- Lack EE. Tumors of the adrenal gland and extra-adrenal paraganglia. Atlas of Tumor Pathology. Third Series, Fascicle 19. Washington, DC : *Armed Forces Institute of Pathology* ; 1997
- Thompson LD. Pheochromocytoma of the Adrenal gland Scaled Score (PASS) to separate benign from malignant neoplasms : a clinicopathologic and immunophenotypic study of 100 cases. *Am J Surg Pathol* 2002 ; 236 : 551-566
- Wu D, Tischler AS, Lloyd RV, DeLellis RA, de Krijger R, van Nederveen F, Nose V. Observer variation in the application of the pheochromocytoma of the adrenal gland scaled score. *Am J Surg Pathol 2009* ; 33 (4) : 599-608
- Agarwal A. Size of the Tumor and Pheochromocytomas of the Adrenal Gland Scaled Score (PASS): Can they predict malignancy? *World J Surg* 2010 ; 34 : 3022-3028